VIA MEDICA

CASE REPORT

Cardiology Journal
2011, Vol. 18, No. X, pp. 1–x
Copyright © 2011 Via Medica
ISSN 1897–5593

Pheochromocytoma-induced reverse tako-tsubo with rapid recovery of left ventricular function

Nasim Naderi[1], Ahmad Amin[1], Ali Setayesh[2], Hamidreza Pouraliakbar[3], Kambiz Mozaffari[4], Majid Maleki[5]

[1]Department of Heart Failure and Transplantation, Shaheed Rajaei Cardiovascular, Medical and Research Center, Tehran University of Medical Sciences, Tehran, Iran
[2]Vascular Surgeon, Shaheed Rajaei Cardiovascular, Medical and Research Center, Tehran University of Medical Sciences, Tehran, Iran
[3]Department of Radiology, Shaheed Rajaei Cardiovascular, Medical and Research Center, Tehran University of Medical Sciences, Tehran, Iran
[4]Department of Pathology, Shaheed Rajaei Cardiovascular, Medical and Research Center, Tehran University of Medical Sciences, Tehran, Iran
[5]Shaheed Rajaei Cardiovascular, Medical and Research Center, Tehran, Iran

Abstract

Pheochromocytoma is a rare, catecholamine-secreting tumor of neuroendocrine cells. It has been documented to present atypically as myocardial ischemia, arrhythmias, or congestive heart failure. We present the case of a patient who had transient cardiomyopathy with hypokinesia of the basal portions of the left ventricle and hyperkinesia of the apex triggered by a pheochromocytoma crisis similar to that of tako-tsubo cardiomyopathy, but with an inverse left ventricular contractile pattern ('inverted tako-tsubo'). (Cardiol J 2011; 18, x: xx–xx)

Key words: pheochromocytoma, tako-tsubo cardiomyopathy

Introduction

Pheochromocytoma is a rare, catecholamine--secreting tumor of neuroendocrine cells that accounts for less than 0.1% of hypertension [1]. The classic symptoms are headache, diaphoresis, and tachycardia with paroxysmal hypertension. Pheochromocytomas have been documented to present atypically as myocardial ischemia, arrhythmias, or congestive heart failure [1]. We herein describe a patient who had transient cardiomyopathy with hypokinesia of the basal portions of the left ventricle (LV) and hyperkinesia of the apex, triggered by a pheochromocytoma crisis. This case seems to confirm recent publications suggesting a new or variant clinical entity with a clinical presentation similar to that of tako-tsubo cardiomyopathy, but with an inverse LV contractile pattern (so-called 'inverted tako-tsubo').

Case report

A 31 year-old woman was admitted because of sudden onset palpitations, fatigue, dyspnea, headache, and diaphoresis. She had no significant past medical history except for a gunshot trauma at six years of age and recent urinary tract infection.

On admission, the patient seemed anxious and agitated. Her blood pressure was 200/120 mm Hg, heart rate was 120 bpm, and body temperature was

Address for correspondence: Nasim Naderi, MD, Cardiologist, Fellowship in Heart Failure and Transplantation, Assistant Professor of Cardiology, Heart Failure and Transplantation Department, Shaheed Rajaei Cardiovascular, Medical and Research Center, Tehran University of Medical Sciences, Vali Asr Avenue, Niayesh Blv, Tehran, Iran, tel: +98 21 23922115, +98 912 2013566, fax: +98 21 22055594, e-mail: naderi.nasim@gmail.com

Received: 02.06.2011 Accepted: 09.08.2011

normal; but she had flushing and profound sweating. Oxygen saturation in room air was 92%. The physical examination of the head and neck was unremarkable and there was no thyromegaly or bruit on the thyroid gland.

Lung auscultation revealed clear lung fields, and cardiovascular examination showed tachycardia and normal rhythm but no murmurs, rubs, or gallops. Abdominal examination was unremarkable except for a previous surgery scar in the right periumbilical area. The radial, femoral, and dorsalis pedis pulses were present and symmetric bilaterally, albeit filiform. The extremities were without edema, tenderness, cyanosis, or clubbing. Skin was cold and wet without striae, hyperpigmentation, or color changes. Neurological assessments of the cranial nerves, motor system, and deep tendon reflexes, as well as the sensory examination, were unremarkable. Blood tests were normal as regards hemoglobin, coagulative parameters, blood sugar, creatinine, serum electrolytes, and liver function. Cardiac enzymes on admission to the Emergency Department showed an increase in troponin I (0.18, normal < 0.1 ng/mL) and creatine kinase-MB (40, normal: 0–25). Electrocardiogram obtained on admission showed sinus tachycardia, normal axis, peaked P wave, and generalized upslope ST depressions. Transthoracic echocardiography demonstrated a normal-sized LV, severe hypokinesia of the base and mid of the anterior and anteroseptal walls, septum, the basal, and mid lateral wall, relatively good apical contraction, ejection fraction (EF) of 30%, grade III LV diastolic dysfunction, mild mitral regurgitation, normal right ventricular size and function, and absence of pericardial effusion or pulmonary hypertension (Figs. 1A, B).

In the Coronary Care Unit, the patient was initially treated with *i.v.* nitroglycerin and furosemide and captopril, but subsequently, given the acute heart failure symptoms accompanied by high blood pressure and signs of catecholamine excess, with an impression of pheochromocytoma, *i.v.* labetolol (2 mg/min) was administered despite a reduced LV function. After an hour, blood pressure, heart rate, sweating, flushing, headache, and agitation decreased. Computed tomography (CT) scan of the brain revealed no abnormality. Because of the high clinical suspicion of pheochromocytoma, abdominal CT scan with *i.v.* contrast was performed and showed a round lesion 35 × 33 mm in size in the right adrenal gland on the short axis with a well-defined outline and solid nature. Post-contrast medium on dynamic and early delayed images showed

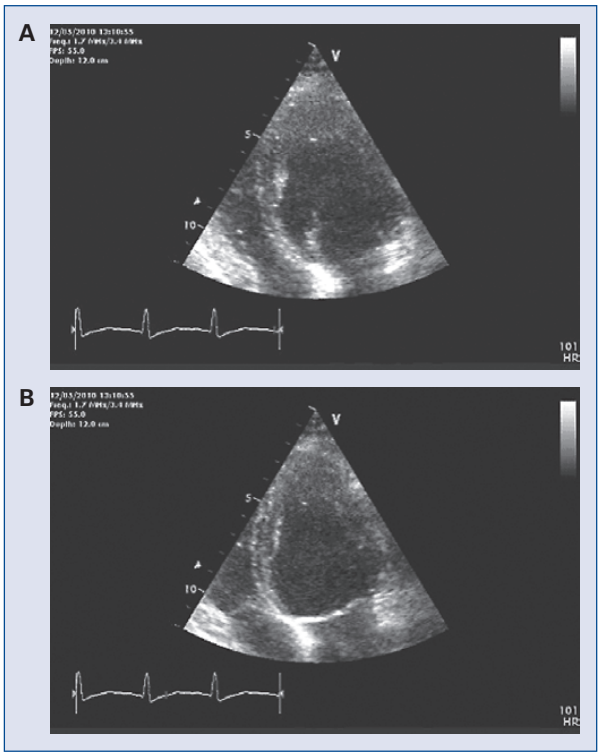

Figure 1. Apical four-chamber view of patient during left ventricular diastole (**A**) and systole (**B**) in acute phase.

mild peripheral enhancement. The left adrenal gland and the other abdominal structures were normal (Figs. 2A–C).

On the second day of the patient's admission, her condition remarkably improved. Blood pressure was controlled and despite tachycardia (heart rate 100–110 bpm), sweating and flushing disappeared. On the third day of admission, transthoracic echocardiography was performed and showed normal LV size and systolic function (LVEF 55%), with no wall motion abnormality, grade I LV diastolic dysfunction, normal right ventricular size and function, trivial mitral regurgitation, no tricuspid regurgitation, and no pulmonary arterial hypertension (Figs. 3A, B). These findings being more compatible with pheochromocytoma, the patient's urine was tested for vanillylmandelic acid and metanephrine (Table 1), and treatment with phenoxybenzamine was started, followed by propranolol 24 h later.

The patient was thereafter referred for surgery in good physical condition and with normal blood pressure and heart rate. The adrenal tumor was resected successfully, and pathological assessment confirmed the presence of pheochromocytoma (Figs. 4, 5).

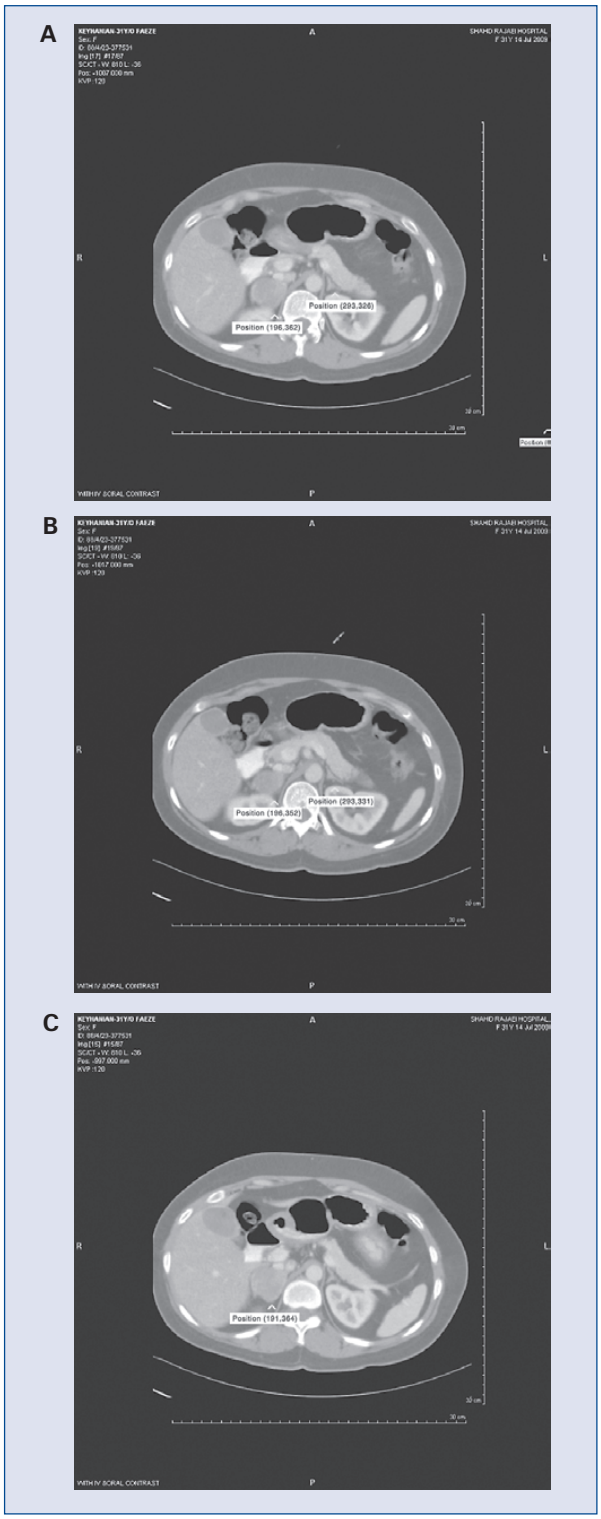

Figure 2. There is a mass lesion with 36 × 34 mm in right adrenal gland without calcification or cystic changes. Relative enchancement after IV contrast administration was detected. The most probable differential diagnosis of these features could be pheochromocytoma or adenoma. Other mass lesion of adrenal gland tumors less probably considered. No remarkable findings at other anatomic sites was detected.

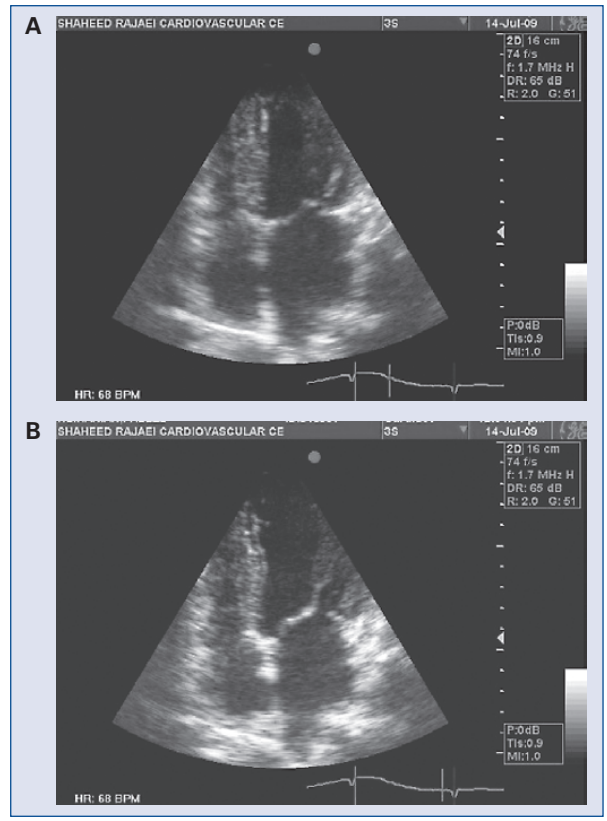

Figure 3. Apical four-chamber view of patient during left ventricular systole (**A**) and diastole (**B**) after recovery.

Table 1. The results of the 24 h urine sample

Metanephrine [μg/24 h]	1,750	Normal < 350
VMA [mg]	23.8	Normal < 13.6
Creatinine [mg/kg]	12.4 mg/kg	Normal 11–20
Urine volume [mL]	1,250 mL	Normal 600–1,800

VMA — vanillylmandelic acid

Discussion

The case presented herein demonstrates myocardial stunning secondary to severe catecholamine excess, with the rapid recovery of the LV function. The patient initially demonstrated profound myocardial dysfunction presenting as acute heart failure with a severely depressed LVEF.

Stress-related cardiomyopathy, or tako-tsubo cardiomyopathy, is a well-described entity characterized by a typical contractile abnormality consisting of apical and mid-ventricular akinesis or dyskinesis and hyperkinesis of the base [2–4]. Severe generalized hypokinesis and tako-tsubo LV dysfunction have been described in pheochromocytoma-

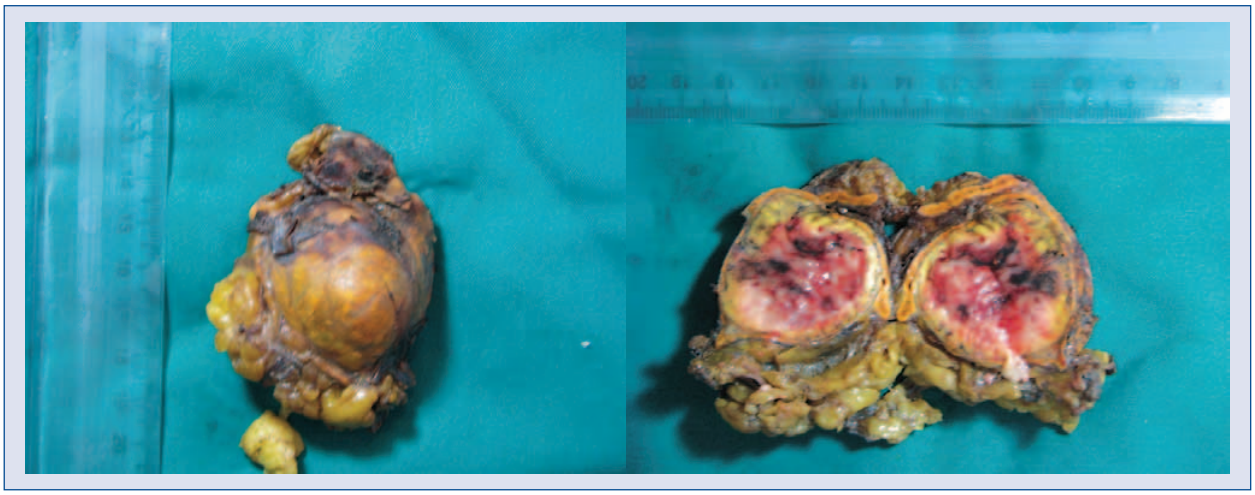

Figure 4. Gray pink pheochromocytoma. A solid tumor with areas of hemorrhage is enclosed by an attenuated cortex. The comma-shaped residual adrenal is seen in the periphery.

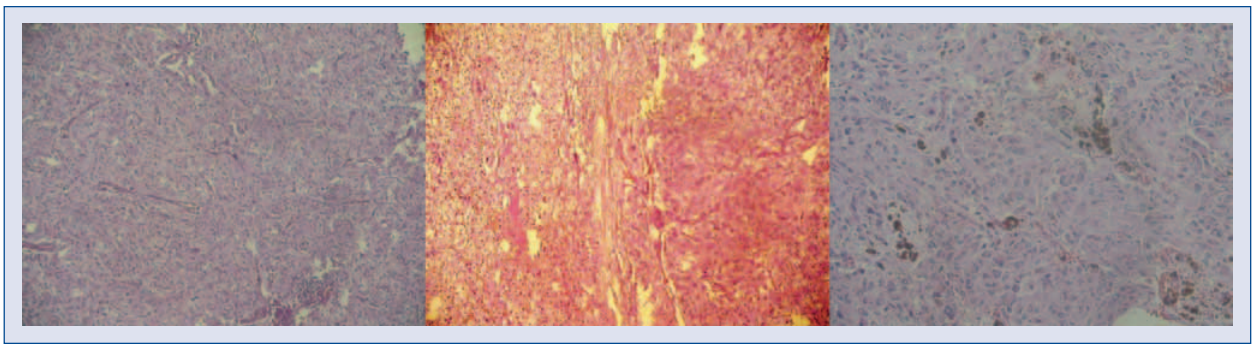

Figure 5. The cells have mild nuclear pleomorphism and abundant granular cytoplasm. The cell nests acquired an organoid pattern (ZELLBALLEN) in a prominent fibrovascular stroma.

related cardiomyopathy [2]. The physiopathologies of stress-induced cardiomyopathy and pheochromocytoma-induced cardiomyopathy are believed to be similar and mediated by catecholamines [2]. Our patient had severe LV dysfunction with different contractile abnormalities: the basal and mid-ventricular segments were hypokinetic, whereas the apex showed hyperkinesia. Therefore, there is no unique ventricular dysfunction pattern in catecholamine-related cardiomyopathy. Regional differences in adrenergic sensitivity or innervation could then explain different clinical presentations with other regions of hypokinesia. A recent report of a pheochromocytoma-related cardiomyopathy with an inverted tako-tsubo contractile pattern supports this hypothesis [2].

Case reports of catecholamine-induced cardiomyopathy and myocardial stunning, either from pheochromocytoma or sudden emotional stress, have shown that cardiac dysfunction can be reversible. Reported recovery times as documented by serial echocardiography have varied from three weeks to over a year [3, 4]. Our patient improved within 48 h of presentation, and her LVEF returned to baseline by day three of hospitalization. To the best of our knowledge, our patient had the shortest reported length of time for the recovery of LV function from a release of excess catecholamines.

Various mechanisms of the cardiotoxic effects of catecholamines have been postulated, including: (1) coronary vasoconstriction via $\alpha 1$ stimulation causing hypoxia and subendocardial injury; (2) norepinephrine-mediated increased concentrations of Ca^{2+} in the sarcoplasma causing myocardial necrosis; (3) increased oxygen demand secondary to increased inotropy, chronotropy, and afterload leading to ischemia; (4) hypothesized increase in free radicals impairing sodium and calcium transporters, thus impairing contractility; and (5) maintained, but

not well-defined, tachyarrhythmias for an unknown amount of time, whether they be of ventricular origin or atrial with associated aberration. Given the patient's markedly elevated cardiac biomarkers, ischemia secondary to vasospasm with a prolonged arrhythmia was the likely culprit for the acute deterioration of cardiac function [5].

Once the diagnosis of pheochromocytoma is considered, the cornerstone of therapy is adequate α-adrenergic blockade. Labetolol, which is both an α- and a β-blocker, in a short period of time brought about improvement in our patient's condition and resolved the crisis. Thereafter, low doses of phenoxybenzamine were titrated until hypertensive fluctuations began to disappear. During this transition time, the patient was treated with intermittent doses of i.v. nitroglycerin for hypertensive crisis. Once adequate α-adrenergic blockade is obtained, low doses of β-adrenergic blockade can be initiated. Premature initiation of β-adrenergic blockade can result in cyclical hypertension from beta-mediated vasodilatation in the skeletal muscle. It should be noted that most patients should not proceed to surgery unless they have been adequately treated with phenoxybenzamine for at least ten days [5].

Despite the rarity of the tumor, this case demonstrates the utility of evaluating for pheochromocytoma, based on the patient's history and clinical suspicion, as it may identify a reversible cause of both hypertension and cardiomyopathy.

Acknowledgements

The authors do not report any conflict of interest regarding this work.

References

1. Awada SH, Grisham A, Woods SE. Large dopamine-secreting pheochromocytoma: case report. Southern Med J, published: 10/17/2003,www.medscape .com.
2. Sanchez-Recalde A, Costero O, Oliver JM, Iborra C, Ruiz E. Pheochromocytoma-related cardiomyopathy inverted takotsubo contractile pattern. Circulation, 2006; 113: e738–e739.
3. Van De Walle SOA, Gevaert SA, Gheeraert PJ. Transient stress--induced cardiomyopathy with an "inverted takotsubo" contractile pattern. Mayo Clin Proc, 2006; 81: 1499–1502.
4. Aurigemma GP. Acute stress cardiomyopathy and reversible left ventricular dysfunction. Cardiol Rounds, 2006; 10: 1–6.
5. Wu GY, Doshi AA, Haas GJ. Pheochromocytoma induced cardiogenic shock with rapid recovery of ventricular function. Eur J Heart Fail, 2007; 9: 212–214.