

# Perforation by permanent pacemaker lead: How late can they occur?

Md. Azizul Haque, Suvanan Roy, Bhabatosh Biswas

B M Birla Heart Research Centre Cardiology, Kolkata, India

## Abstract

*Perforation by permanent pacemaker lead is rare but does occur. Usually perforations happen soon after the procedure, mostly within one year. But rarely, they occur late. We report a case of delayed perforation by passive fixation lead 33 weeks after the implantation in a patient with no comorbidities. The patient remained asymptomatic regarding the perforation except for having the features of pacing failure. (Cardiol J 2011; 18, X: xx–xx)*

**Key words:** pacemaker, late perforation, lead

## Case report

A 49 year-old lady presented with exercise intolerance with intermittent episodes of presyncope for three months. She had one episode of syncope also two weeks prior to presentation. She did not have any other comorbidities. Three years ago, she had similar symptoms. She was found to have bifascicular block (RBBB with LAHB) with intermittent third degree atrioventricular block, for which a DDD pacemaker had been implanted in right infraclavicular region at that time. Atrial lead was screw-in lead and ventricular lead was tined in nature. Procedure was uneventful and she was under regular follow-up post-procedure. The last permanent pacemaker (PPM) check-up was done six months prior to presentation. At that time, all the PPM parameters were within acceptable limits. This time, on pacemaker interrogation, it became evident that sensing and pacing parameters of atrial lead were normal, but there was total sensing and capture failure of the ventricular lead. Patient was hemodynamically stable. X-ray chest (PA view) gave rise to suspicion of ventricular lead displacement outside pericardium. Computed tomography-thorax confirmed the lead migration and tip of ventricular lead was found to be much outside the pericardium, within lung parenchyma (Figs. 1, 2). There

was no pericardial effusion or tamponade. So a diagnosis of perforation by PPM lead was made.

As the lead was tined and therefore with bulky tips, and as it had migrated too far, transvenous lead extraction would have been difficult and risky. So, open surgery was chosen to extract the lead. Under general anesthesia, thorax was opened. Lead was easily located inside lung parenchyma and transected. The proximal part of the lead was then pulled transvenously. It came out without any problem. Right ventricle (RV) was repaired under direct vision. A new lead was positioned in RV through subclavian puncture. Patient recovered well. She has been under regular follow-up and without problems for the last two years.

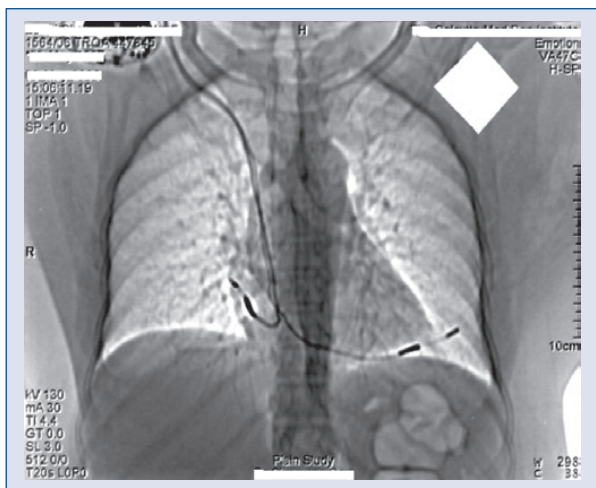
## Discussion

Cardiac perforation by PPM lead is rare, but well known and has been reported in literature [1]. The reported rate of perforation is around 0.1–0.8%. Most of the perforations occur during lead manipulation during implantation and may perforate into great veins, atria or in the ventricles. But on rare occasions, perforations can take place long after the implant procedure. Possibly, redundant loop with constant extra-pressure exerted by the lead to the ventricular site leads to perforation. But the most

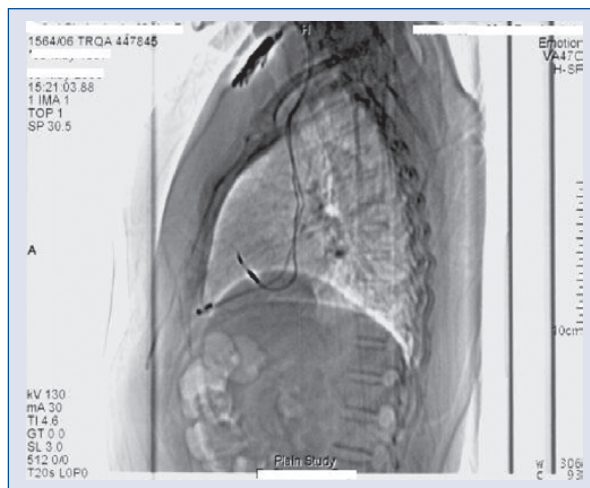
**Address for correspondence:** Md. Azizul Haque, MD, Sugam Ashray, 22/2D, Gorachand Road, Park Circus, Kolkata, West Bengal-700014, India tel: 9830144740, e-mail: azizul1234@hotmail.com

Received: 15.07.2011

Accepted: 21.07.2011



**Figure 1.** Computed tomography scan showing perforated ventricular lead outside cardiac shadow.



**Figure 2.** Computed tomography scan showing perforated ventricular lead — lateral view.

intriguing fact in this patient is the long delay between the implantation and perforation by passive fixation lead. As she was under regular supervision and follow-up, and she had her last check-up six months prior to presentation, it may be said that perforation took place after that. Her symptoms developed three months before presenting to us, so it may be presumed that she experienced perforation 33 months after implantation, which is a very long time. One possibility might be that the lead had been progressively burrowing throughout those months, but continued to capture because it was within myocardium. Once it came perforating outside the myocardium, which may be due to raised intrathoracic pressure due to any reason, she developed symptoms due to pacing failure. Singhal et al. [2] has reported one case where perforation came to attention seven years after implantation because of infection, but the exact time of perforation was difficult to ascertain. Alla et al. [3] reported a case of late perforation close to five years after implantation, but the patient was an 84 year-old lady with rheumatoid arthritis on long-term steroids. Our patient did not have any known risk factors except female gender. Common risk factors reported for perforation are: female gender, old age, active fixation leads, use of corticosteroids, prior temporary pacing.

The second notable feature in this patient was that she was completely asymptomatic of the perforation. Perforation itself did not produce any complications like pericardial effusion, cardiac tamponade or hemothorax. Possibly the chronic nature of the perforation saved her from acute emergencies. There are reports of similar uncomplicated perforations in the literature.

PPM perforation, though rare, can happen in patients and unfortunately it can occur much later in the course, as happened in this case. And chronic perforations may be devoid of any symptoms except pacing and sensing failure.

### Acknowledgements

The authors do not report any conflict of interest regarding this work.

### References

1. Carlson MD, Freedman RA, Levine PA. Lead perforation: Incidence in registries. *Pacing Clin Electrophysiol*, 2008; 31: 13–15.
2. Singhal S, Cooper JM, Cheung AT et al. Rib perforation from a right ventricular pacemaker lead. *Circulation*, 2007; 115: e391–e392.
3. Alla VM, Reddy YM, Abide W, Hee T, Hunter C. Delayed lead perforation: Can we ever let the guard down? *Cardiol Res Pract*, 2010; pii. 741751.