

# Symptoms in the presence of a giant windsock eustachian valve remnant

Abhishek Chauhan<sup>1\*</sup>, Girish Dwivedi<sup>1\*</sup>, Robert H. Anderson<sup>2</sup>, Robert J. MacFadyen<sup>1</sup>

<sup>1</sup>University of Birmingham, Birmingham, United Kingdom

<sup>2</sup>University of Manchester, Manchester, United Kingdom

## Abstract

*We present the case of a 43 year-old female with an isolated episode of atypical chest pain and an ill-defined cardiac murmur who was coincidentally found to possess a large serpiginous residual embryonic structure in right atrium. Multiple modality imaging was required to confirm this to be a rare giant eustachian valve remnant. The eustachian valve in the fetus directs oxygenated blood towards the foramen ovale. While absent or very small in adult life it rarely persists to any significant degree and must be distinguished from other right atrial shelf anomalies. The true potential of these structures to cause pathological interference with cardiac function or symptoms is unknown due to their rarity. (Cardiol J 2011; 18, X: xx–xx)*

**Key words:** eustachian valve, right atrium, foramen ovale

## Case report

An otherwise well 43 year-old female of Chinese descent with no communication in English presented to our hospital with an isolated episode of nocturnal chest pain. She had been resident in the United Kingdom for a short period of time and was referred with no coherent diagnosis for ongoing symptoms. Through an interpreter, her description was of episodic cramping abdominal pain and diarrhea, after eating a take-away meal. She had experienced non-exertional left-sided chest discomfort, radiating to the back and pain associated with mild sweating, light-headedness and nausea. She had no coherent cardiac symptoms and no risk factors for atherosclerosis. There was no family history in China of cardiac disease or sudden death, nor had any abnormalities been found during pregnancy.

Her examination revealed sinus rhythm with blood pressure of 114/72 mm Hg. Peripheral pulses were palpable and there was no radio femoral

delay. Jugular venous pressure was not elevated and hepato-jugular reflux was negative. Chest was clear on auscultation. Cardiovascular examination revealed a normal apex with first and second heart sounds. A soft ejection systolic murmur was heard in the aortic region. Abdominal examination was unremarkable. Her 12-lead electrocardiogram showed normal axis with a borderline PR interval of 206 ms. Her chest X-ray was unremarkable. In view of the presence of a non-specific murmur and first-degree atrioventricular block, an outpatient transthoracic echocardiogram (TTE) was booked with the intention of ruling out an occult atrial septal defect (ASD).

## Progress and investigation

The patient remained asymptomatic with no recurrence of symptoms and no emergent diagnosis. Subsequent TTE revealed a very large tethered serpiginous structure mobile in the right atrium (RA) and prolapsing towards the tricuspid valve

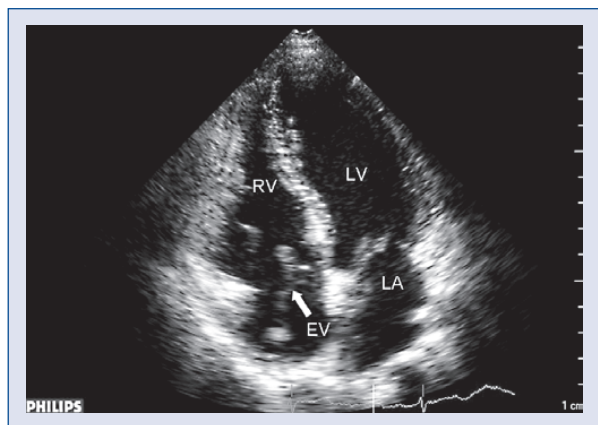
---

**Address for correspondence:** Dr Girish Dwivedi, MD, DM, MRCP (UK), PhD, Clinical Lecturer in Cardiology, Department of Cardiovascular Medicine, The Medical School, University of Birmingham, Edgbaston, Birmingham, B15 2TT, United Kingdom, tel: +44 121 5075080, e-mail: g.dwivedi@bham.ac.uk

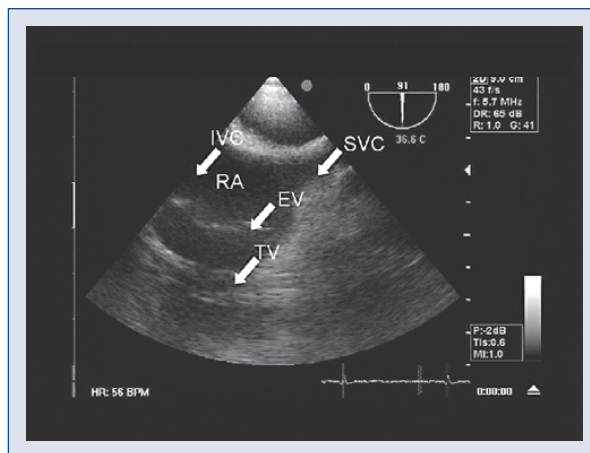
\*These authors contributed equally to this work

Received: 30.07.2011

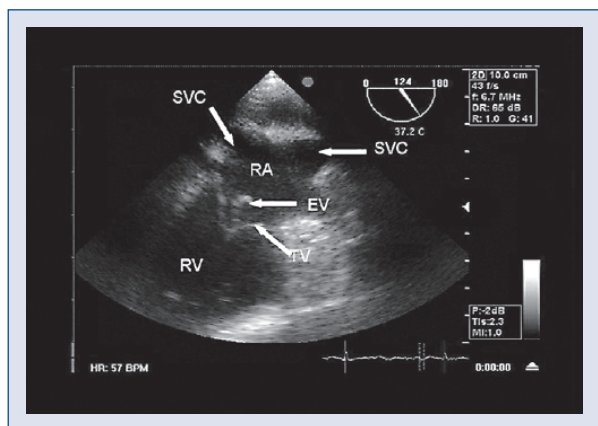
Accepted: 04.08.2011



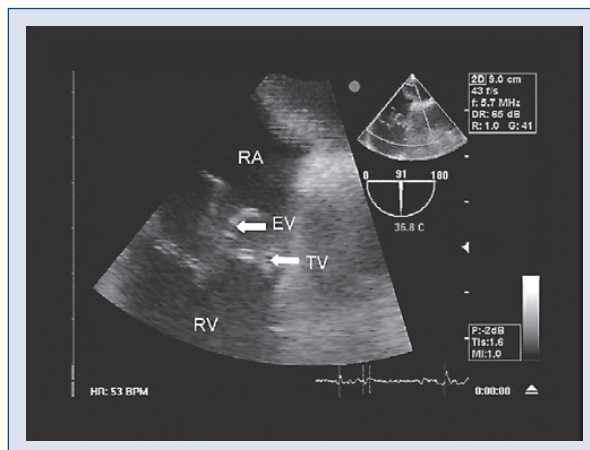
**Figure 1.** Apical four-chamber transthoracic echocardiogram, demonstrating a large tethered, serpiginous structure mobile in the right atrium and prolapsing towards the tricuspid valve; RV — right ventricle; LV — left ventricle; LA — left atrium; EV — eustachian valve.



**Figure 3.** Transesophageal echocardiogram image, giving appearance of a divided right atrium; IVC — inferior vena cava; SVC — superior vena cava; EV — eustachian valve; TV — tricuspid valve.



**Figure 2.** Bicaval view on transesophageal echocardiogram, confirming the site of origin and location of the structure; SVC — superior vena cava; RA — right atrium; RV — right ventricle; EV — eustachian valve.



**Figure 4.** Transesophageal echocardiogram image, showing interference with tricuspid valve closure and right ventricular filling; RA — right atrium; EV — eustachian valve; TV — tricuspid valve; RV — right ventricle.

(Fig. 1). The tricuspid valve apparatus appeared anatomically and functionally intact, as did the rest of the heart. There was no suggestion of Ebstein anomaly; ASD; right ventricular outflow tract anomaly, or other valvular lesion. The large ‘windsock lesion’ in the RA anomaly arose predominantly from the junction of inferior vena cava (IVC) with the RA. A probable diagnosis of a eustachian valve (EV) was considered, but the massive nature of the anomaly prompted further investigation.

A transesophageal echocardiogram (TEE) was performed to confirm the site of origin and also better define the nature of the structure (Fig. 2). It

demonstrated its exceptionally mobile character and in one plane gave the appearance of a divided RA (Fig. 3). On TEE imaging, it appeared that there was some interference with tricuspid valve closure and right ventricular filling (Fig. 4). There was no significant regurgitation or obstructive gradient across the tricuspid valve. Three-dimensional TTE imaging provided no greater detail.

The patient subsequently underwent cardiac magnetic resonance imaging to confirm the above findings, but more definitively help to rule out the prospect of a divided RA.

## Discussion

During fetal life, the EV, which is of variable size, diverts oxygenated blood away from the tricuspid valve through the patent foramen ovale and increases the delivery of oxygenated blood to the left ventricle. After delivery, the EV will regress and is normally absent in adulthood. Large remnant EVs can mimic atrial tumors, intra cardiac thrombosis or even vegetations [1].

Where present in the adult human, the EV is vestigial and takes the form of a thin ridge-like crescent [2]. The crescentic fold of the endocardium can contribute one form of RA shelf and generally arises from the anterior rim of the IVC orifice. The lateral horn of the crescent tends to meet the lower end of the crista terminalis, while the medial horn joins the thebesian (or coronary sinus) valve.

These structures are generally found by chance after unrelated physical examination and/or echocardiographic imaging has been performed for another reason. As in this instance, the EV appears as a serpiginous and often fenestrated structure arising from the anterior aspect of the IVC. While they float freely within the RA cavity, they are generally small and easily recognized. If the structure and its attachment are large enough, they can give the appearance of a 'divided atrium'.

The previous anatomical terminology of *cor triarteriosum dexter* was first suggested in 1868. The RA can be divided into two parts (potentially completely) by a fold of tissue, a membrane, or a fibromuscular band. Classically, the proximal (upper or superior) portion of the corresponding atrium receives venous blood, whereas the distal (lower or inferior) portion is in contact with the tricuspid valve and contains the RA appendage and the true atrial septum that bears the fossa ovalis [2]. The membrane that separates the atrium into two parts may be imperforate or bear one or more fenestrations [3]. There can also be an associated ASD in continuity with the superior portion of the divided atrium, resulting in a right to left shunt and subsequent cyanosis. The presence of the ASD and cyanosis distinguishes *cor triarteriosum dexter* from giant EVs [1].

Remnant EVs are generally thought to be benign structures. However, recent assessments suggest that persistent EV may predispose to patency of the foramen ovale [3]. While a patent foramen ovale in patients with pulmonary embolic disease is associated with a ten-fold increase in death and a five-fold increase in the risk of adverse outcomes during the hospital stay [4], the added risk of a persistent EV may increase the risk of embolic thrombosis to the left atrium and arterial circulation [3].

There are anecdotal reports of aborted pulmonary embolism due to a giant persistent EV [5].

While a persistent EV may serve as a site for the development of right-sided infection or thrombosis and/or embolization, it is unclear just how common these remnants are and how often they mediate true pathology [6, 7]. Infective endocarditis based on an infected EV has been described, but only in exceedingly vulnerable subjects such as intravenous drug users [8–10]. Lastly, the presence of an EV remnant can make interventional procedures such as closure of an ASD and ablation for atrial flutter technically more challenging.

## Treatment

This patient was asymptomatic and her EV remnant, however large and striking in appearance, had no functional impact on her right heart function. Her symptoms were largely coincidental and have not recurred. Removing these structures by surgical excision has been done, but the rationale for doing so in the absence of symptomatic linkage, exercise limitation and/or a direct problem with infection or thrombosis, is obscure. The patient was kept under symptomatic review only.

## Acknowledgements

The authors do not report any conflict of interest regarding this work.

## References

1. Yavuz T, Nazli C, Kinay O, Kutsal A. Giant eustachian valve with echocardiographic appearance of divided right atrium. *Texas Heart Inst J*, 2002; 29: 336–338.
2. Watson T, Kakar P, Srivastava S, Dhanjal TS. Eustachian valve remnant. *Cardiol J*, 2007; 14: 508–509.
3. Schuchlenz HW, Saurer G, Weihs W, Rehak P. Persisting eustachian valve in adults: Relation to patent foramen ovale and cerebrovascular events. *J Am Soc Echocardiogr*, 2004; 17: 231–233.
4. Konstantinides S, Geibel A, Kasper W, Olschewski M, Blümel L, Just H. Patent foramen ovale is an important predictor of adverse outcome in patients with major pulmonary embolism. *Circulation*, 1998; 97: 1946–1945.
5. De Keyser JL, Herregods MC, Dujardin K, Mullens W. The Eustachian valve in pulmonary embolism: Rescue or perilous? *Eur J Echocardiogr*, 2006; 7: 336–338.
6. Escota-Villanueva J, Lacambra-Blasco I, Gonzalvo C. Images in cardiovascular medicine. Eustachian valve thrombosis. *Circulation*, 2008; 118: e504.
7. Maddury J, Alla VM, Misra RC, Maddavapeddi A. Thrombus on the eustachian valve leading to recurrent pulmonary embolism: A rare problem requiring aggressive management. *Can J Cardiol*, 2009; 25: e422–423.
8. Veiga VC, Molinari AC, Farias CM et al. Eustachian valve endocarditis. *Arq Bras Cardiol*, 2007; 88: e79–e80.
9. Gill DS, Birchley S. Eustachian valve endocarditis. *Echocardiography*, 2006; 23: 256–257.
10. Pellicelli AM, Pino P, Terranova A, D'Ambrosio C, Soccorsi F. Eustachian valve endocarditis: A rare localization of right side endocarditis. A case report and review of the literature. *Cardiovasc Ultrasound*, 2005; 19: 30.