

Ablation of a left lateral accessory pathway in a patient with dextroposition of the heart

Adrian Baranchuk, Riyaz Somani, Christopher S. Simpson,
Kevin A. Michael, Damian P. Redfearn

Heart Rhythm Service, Kingston General Hospital, Queen's University, Kingston, Ontario, Canada

A 21 year-old male presented with palpitations and syncope. His comorbid pathology included congenital hypoplasia of the right lung, esophageal atresia and Budd-Chiari syndrome ameliorated with a ventriculo-peritoneal shunt. A Wolff-Parkinson-White pattern was identified on a 12-lead electrocardiogram (Fig. 1A) and the patient was referred for an electrophysiological study. A chest X-ray revealed cardiac dextroposition with situs solitus (Fig. 1B) and a subsequent computed tomography scan confirmed atrio-ventricular and ventriculo-arterial concordance (Fig. 1C). During the electrophysiological study, the fluoroscopic antero-posterior projection was equivalent to what would normally be expected in the left anterior oblique view (Fig. 1D). A retrograde trans-aortic approach was

used to ablate the accessory pathway which was localized on the left lateral aspect of the mitral annular ring. Three dimensional mapping was also employed (Ensite, St Jude Medical, St Paul, MN, USA) which highlighted the anterior position of the left ventricle (Fig. 1E). The post ablation ECG, with the precordial leads on the right side of the chest, showed resolution of pre-excitation with T wave memory phenomenon (Fig. 1F). The patient remained asymptomatic after a follow-up period of 36 months.

Acknowledgements

The authors do not report any conflict of interest regarding this work.

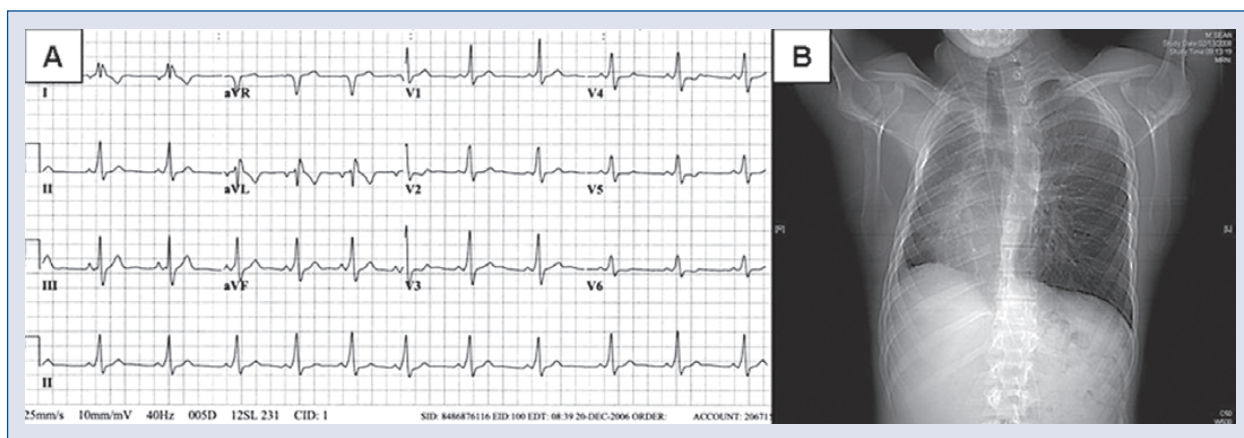


Figure 1. A. 12-lead ECG depicts ventricular pre-excitation through a left lateral accessory pathway (short PR interval + delta waves) in a patient with dextroposition of the heart (negative P-waves in leads I and aVL, reversed R-wave progression from V1 to V6); B. Chest X-ray in the antero-posterior view. The heart is on the right side of the chest. A ventriculo-peritoneal shunt can be seen.

Address for correspondence: Dr Adrian Baranchuk, MD, FACC, Associate Professor of Medicine and Physiology, Cardiac Electrophysiology and Pacing, Kingston General Hospital K7L 2V7, Queen's University, Kingston, Ontario, Canada, tel: 613 549 6666, ext. 3801, fax: 613 548 1387, e-mail: barancha@kgh.kari.net

Received: 16.08.2011

Accepted: 17.08.2011

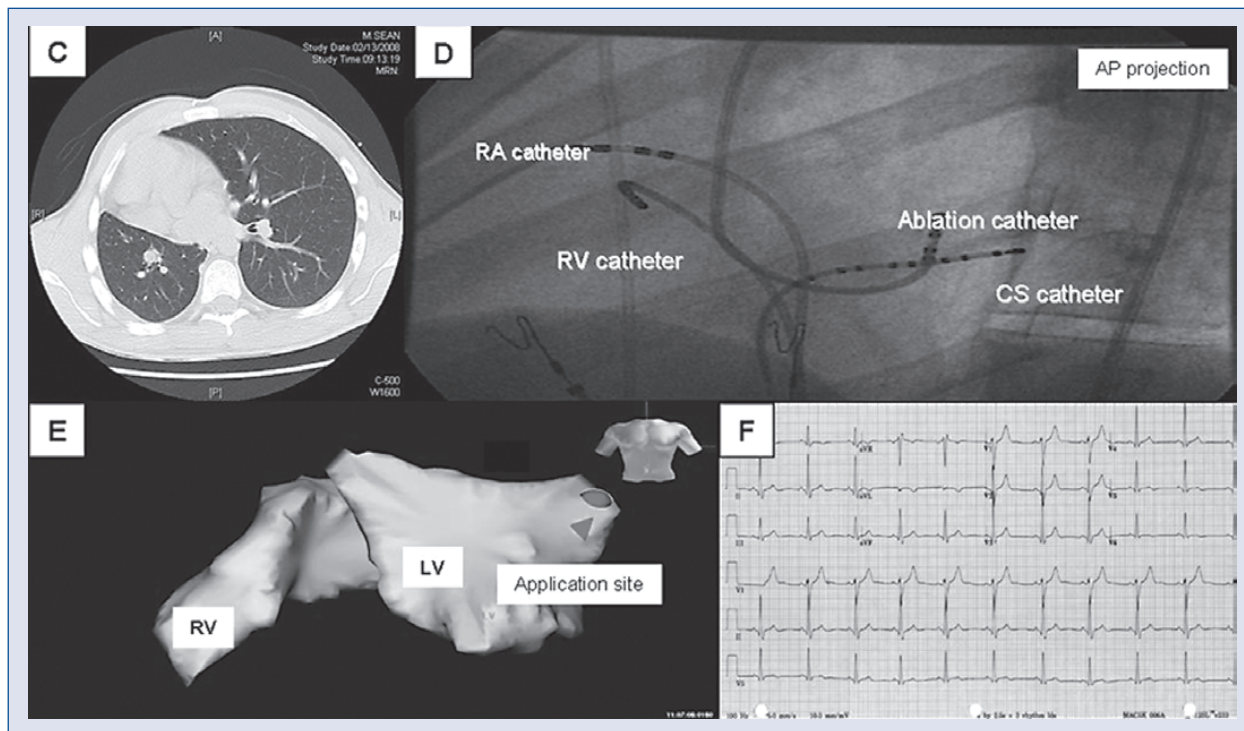


Figure 1. C. A computed tomography (CT) scan of the chest confirmed dextroposition of the heart. There is atrio-ventricular and ventriculo-arterial concordance. Despite the CT scan showing contact between the left and right atria, a trans-aortic approach was preferred for the electrophysiology study; D. Antero-posterior (AP) fluoroscopy projection. With the heart displaced to the right, the AP projection is equivalent to that expected in the left anterior oblique view; RA — right atrium; RV — right ventricle; CS — coronary sinus E. Ensite tridimensional reconstruction of the heart. Antero-posterior view. The left ventricle (LV) is anteriorly positioned; RV — right ventricle; F. Post ablation 12-lead ECG demonstrating normal sinus rhythm with no evidence of pre-excitation. The precordial leads were placed on the right side of the chest. Normal R-wave progression can now be seen. T-wave memory phenomenon is also seen in leads I and aVL.