

# Anterior mitral leaflet perforation identified by real time three-dimensional transesophageal echocardiography

Hsiao-Liang Cheng, Ya-Jung Cheng, Chia-Hsin Lai

Department of Anesthesiology, National Taiwan University Hospital, Taipei, Taiwan

## Abstract

*With its unique en face view, real time three-dimensional transesophageal echocardiography has been reported to be more precise than conventional two-dimensional studies in evaluating mitral regurgitation etiology, and can locate diseased segments correctly. We present a case with severe mitral regurgitation due to anterior mitral leaflet perforation. Intraoperative real time three-dimensional transesophageal echocardiography demonstrated its value in diagnosis and surgical planning for this perforation, which had not been identified preoperatively. This technique should be applied more widely for dedicated mitral valve assessment in clinical practice. (Cardiol J 2011; 18, X: xx–xx)*

**Key words:** RT-3D TEE, mitral valve, mitral regurgitation, endocarditis

A 53 year-old man complained of progressive shortness of breath and lower legs edema with fever. He was admitted to his local hospital where infective endocarditis was diagnosed, as blood culture yielded *Streptococcus parasanguinis* and transthoracic echocardiography (TTE) disclosed severe mitral regurgitation (MR). After intravenous antibiotics treatment for three weeks, he came to our hospital for a second opinion and surgical intervention was arranged. Preoperative TTE showed eccentric MR jet directed posteriorly and anterior mitral leaflet (AML) prolapse was suspected.

In the theatre, we performed real time (RT) three-dimensional (3D) transesophageal echocardiography (TEE) (X7-2t probe with iE33, Philips Medical System, Andover, MA, USA) (Figs. 1, 2) after general anesthesia. With 3D en face view from the left atrium aspect, a perforation on the AML was identified at the middle segment (A2). After off-line

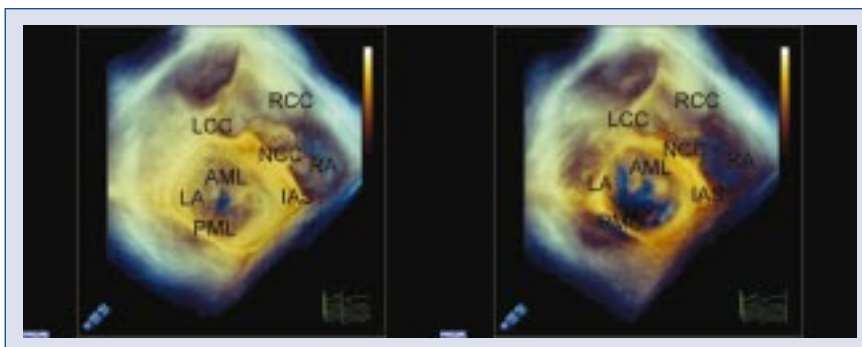
cropping of the 3D dataset, we planimeted the perforation and the estimated width, length, and area were 0.91 cm, 1.12 cm, and 0.93 cm<sup>2</sup> respectively (Fig. 3). There was no prolapse nor flail of the AML. These findings were confirmed by direct inspection intraoperatively and the perforation was measured as 0.8 × 1 cm, well correlated to 3D planimetry. The cardiac surgeon used an autologous pericardial patch to cover the A2 perforation and Wooler's annuloplasty with two coaptation sutures was done. The recovery course of this patient was smooth and there was no major event in our follow-up for 18 months.

Since becoming commercially available in late 2007, RT-3D TEE has made a great advance in the assessment of mitral valve surgery [1]. With the unique en face view, it has been reported to be more precise than conventional two-dimensional (2D) studies in MR differential diagnosis (prolapse, flail,

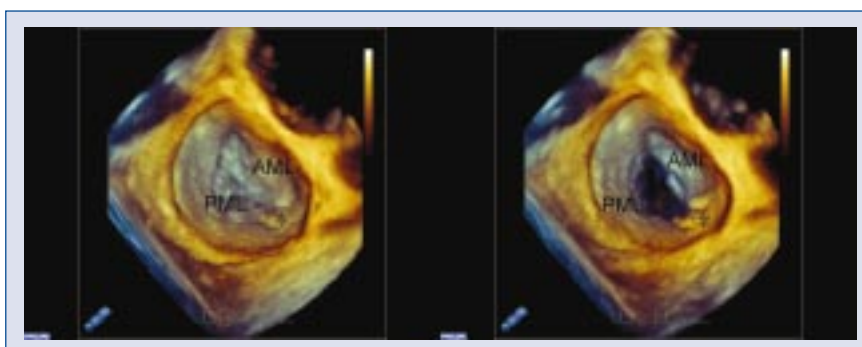
Address for correspondence: Ya-Jung Cheng, MD, PhD, National Taiwan University Hospital, Department of Anesthesiology, No. 7, Chung-Shan S. Rd., Taipei, Taiwan, tel: 886-2-23123456, ext. 62158, fax: 886-2-23415736, e-mail: chengyj@ntu.edu.tw

Received: 23.05.2011

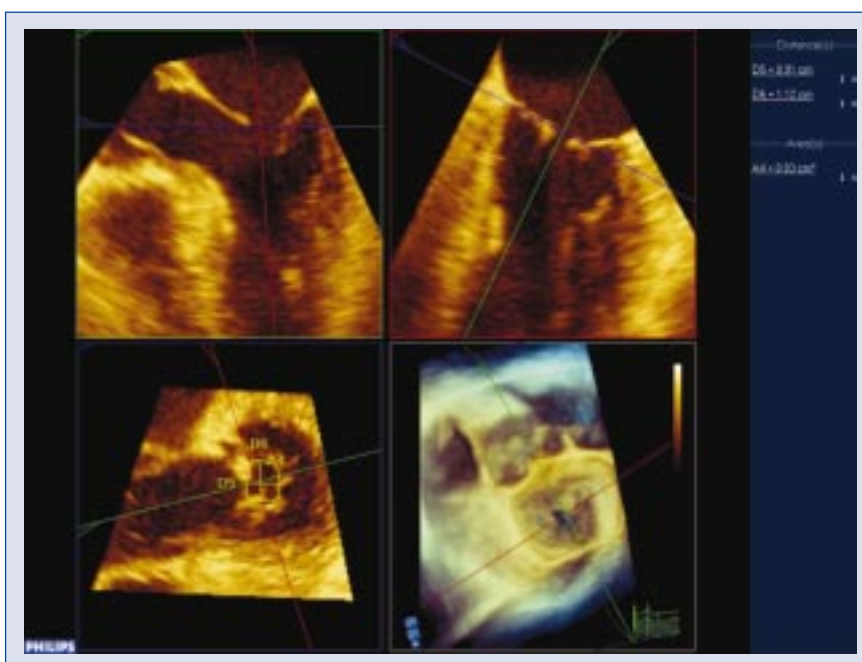
Accepted: 27.06.2011



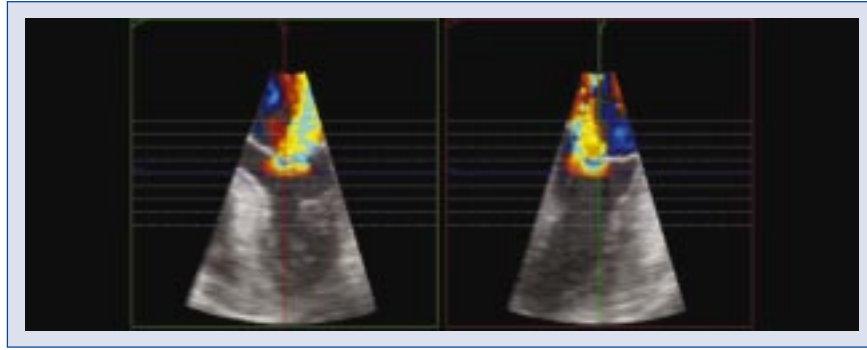
**Figure 1.** Three-dimensional (3D) en face view of mitral and aortic valves. 3D full volume showed en face view of mitral and aortic valves from atrial aspect during systole (left) and diastole (right). The perforation (\*) of anterior mitral leaflet (AML) was identified at middle segment (A2); PML — posterior mitral leaflet; LCC — left coronary cusp; RCC — right coronary cusp; NCC — non-coronary cusp; LA — left atrium; RA — right atrium; IAS — interatrial septum.



**Figure 2.** Three-dimensional (3D) en face view of mitral valve after surgical repair. 3D zoom showed en face view from atrial aspect during systole (left) and diastole (right) after surgical repair. There was no residual perforation after autologous pericardial patch coverage. Coaptation suture (\*) of Wooler’s annuloplasty was also shown; AML — anterior mitral leaflet; PML — posterior mitral leaflet.



**Figure 3.** Three-dimensional (3D) planimetry of the perforation. After off-line cropping of the 3D dataset, we planimetryed the perforation and the estimated width, length, and area were 0.91 cm, 1.12 cm, and 0.93 cm<sup>2</sup>, respectively.



**Figure 4.** Mitral valve assessment. Using 3DQA of Philips QLAB software, we can measure the mitral regurgitation vena contracta in all axes and planes. Direct planimetry of the regurgitant orifice area is also possible.

chorda rupture, congenital anomaly, perforation, cleft etc) and can locate diseased segments (Capentier nomenclature A1, A2, A3, P1, P2, P3) correctly [2, 3].

It is also excellent for educating novices and communicating with the surgical team because the en face view can simulate the surgeon's view and requires no need for 'mental reconstruction'. In addition to RT inspection, off-line quantification on workstations or personal computers by QLAB software provided by Philips is also useful for mitral valve evaluation. With 3DQA modality (Fig. 4), we can measure the MR vena contracta in all axes and planes. Unlike conventional 2D multiplane studies, these views are obtained at the same point in one cardiac cycle.

In conclusion, intraoperative RT-3D TEE demonstrated its value in diagnosis and surgical planning for this AML perforation, which was not identified preoperatively. This technique should be ap-

plied more widely for dedicated mitral valve assessment in clinical practice.

### Acknowledgements

The authors do not report any conflict of interest regarding this work.

### References

1. Vegas A, Meineri M. Core review: Three-dimensional transesophageal echocardiography is a major advance for intraoperative clinical management of patients undergoing cardiac surgery: A core review. *Anesth Analg*, 2010; 110: 1548–1573.
2. Manda J, Kesanolla SK, Hsuing MC et al. Comparison of real time two-dimensional with live/real time three-dimensional transesophageal echocardiography in the evaluation of mitral valve prolapse and chordae rupture. *Echocardiography*, 2008; 25: 1131–1137.
3. Grewal J, Mankad S, Freeman WK et al. Real-time three-dimensional transesophageal echocardiography in the intraoperative assessment of mitral valve disease. *J Am Soc Echocardiogr*, 2009; 22: 34–41.