

A rare congenital anomaly: pulmonary atresia and abnormal origin of right pulmonary artery

Mevlut Koc¹, Kamuran Tekin¹, Zafer Elbasan¹, Durmus Yildiray Sahin¹,
Mustafa Kemal Batur², Murat Cayli¹

¹Department of Cardiology, Adana Numune Education and Research Hospital, Adana, Turkey

²Department of Cardiology, Acibadem University Medical Faculty, Adana, Turkey

A 22 year-old woman presented with dyspnea, central cyanosis and a pulsatile mass on her left neck. Echocardiography showed subaortic ventricular septal defect, aortic overriding and pulmonary atresia. Pulmonary valve and main pulmonary artery (PA) could not be visualized by echocardiography. Multi-detector computed tomography and selective right pulmonary angiography showed the right PA arising from the distal portion of the arcus aorta after the left subclavian artery, but the left PA could not be visualized. The left PA was

supplied by collateral vessel from the right PA. Anomalous origin of a PA from the aorta is a rare malformation. The combination with pulmonary atresia and right PA arising from the arcus aorta has not previously been demonstrated in the literature (Figs. 1, 2).

Acknowledgements

The authors do not report any conflict of interest regarding this work.

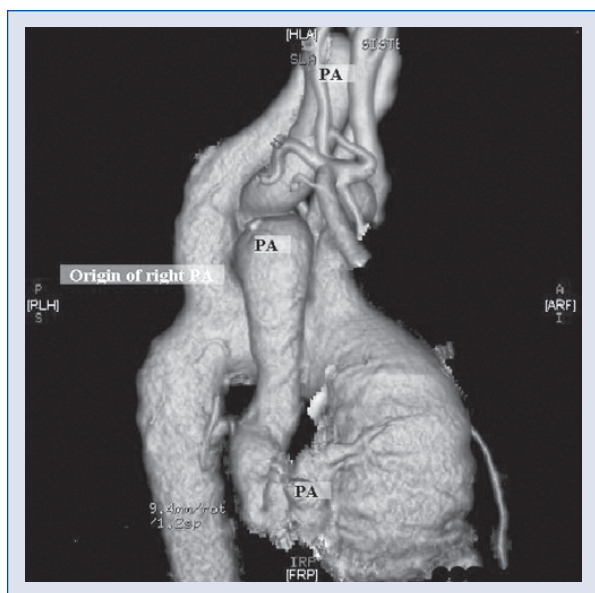

Figure 1. Axial computed tomography image showing right pulmonary artery (PA) arising from the arcus aorta.

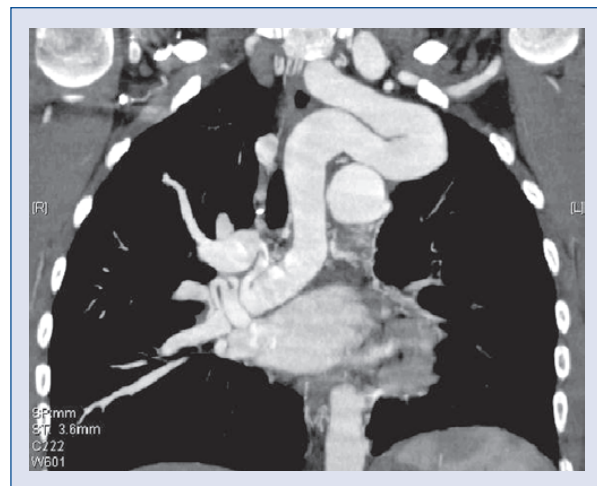


Figure 2. Three-dimensional volume rendering image showing right pulmonary artery (PA) arising from the distal portion of the arcus aorta after the left subclavian artery, but the origin of left PA cannot be visualized. Left PA being supplied by collateral vessel from right PA.

Address for correspondence: Mevlut Koc, MD, Adana Numune Education and Research Hospital, Department of Cardiology, Süleyman Demirel Bulvari, 01330 Adana, Turkey, tel: +90 322 338 69 33, e-mail: mevlutkoc78@yahoo.com

Received: 11.02.2011

Accepted: 30.05.2011