

Intramural hemotoma presenting as acute coronary syndrome: The importance of intravascular ultrasound

Yogesh Raja, Jasper Trevelyan, Sagar N. Doshi

Department of Interventional Cardiology, Queen Elizabeth University Hospital,
Birmingham, United Kingdom

Abstract

Intramural hematoma in major coronary epicardial vessels is a rare cause of chest pain. Afflicted individuals may present with acute coronary syndrome (ACS) or even sudden cardiac death. Spontaneous, isolated intramural hematoma may occur in the absence of associated intimal dissection. In this situation, lesions may be angiographically indistinguishable from ruptured atherosclerotic plaque. Intravascular ultrasound is important in the accurate diagnosis of isolated intramural hematoma. Although coronary stenting may be required in the presence of ongoing ischemia, intramural hematoma may be successfully managed medically. We describe the case of a middle-aged woman who presented with ACS due to an intramural hematoma and discuss the diagnosis and management of this rare illness. (Cardiol J 2011; 18, x: xx–xx)

Key words: intracoronary ultrasound, intramural hematoma, coronary stenting

Introduction

Intramural hematoma in major epicardial coronary vessels is a rare cause of chest pain. Afflicted individuals may present with acute coronary syndrome or even sudden cardiac death [1]. If the hematoma breaches the intima, angiographic appearance of vessel dissection is frequently visible, alerting the clinician to the underlying diagnosis. However, spontaneous, isolated intramural hematoma may occur in the absence of dissection and may be impossible to differentiate from a ruptured atherosclerotic plaque by angiography alone. Correct diagnosis is important because intracoronary stenting is not necessarily the optimal management of intramural hematoma in all cases. We present the case of a middle-aged woman who presented with acute onset of chest pain due to an intramural hematoma and discuss the importance of accurate diagnosis in the management of this rare illness.

Case report

A 44 year-old woman with a history of mild hypertension, not requiring medication, was admitted with sudden onset of cardiac chest pain of 20 minutes' duration. She was a non-smoker, not obese, with no family history of premature coronary disease and no personal history of diabetes or dyslipidemia. Electrocardiogram showed anterior T wave inversion, and troponin T was mildly elevated. Total cholesterol was 4.6 mmol/L on admission. Coronary angiography revealed smooth and normal coronary arteries, apart from the left anterior descending, in which was observed a long section of luminal narrowing in the mid vessel (Fig. 1). This was initially felt to be due to a ruptured atherosclerotic plaque but was interrogated with intravascular ultrasound (IVUS), as other vessels appeared normal and because of the paucity of traditional risk factors for atherosclerosis.

Address for correspondence: Dr Sagar N. Doshi, BSc, MD, FRCP, Cardiology Department, Queen Elizabeth University Hospital, Edgbaston, Birmingham, B15 2TH, tel: 0044 07979 806314, fax: 00 44 121 697 8304, e-mail: Sagar.Doshi@uhb.nhs.uk

Received: 08.01.2011

Accepted: 23.02.2011

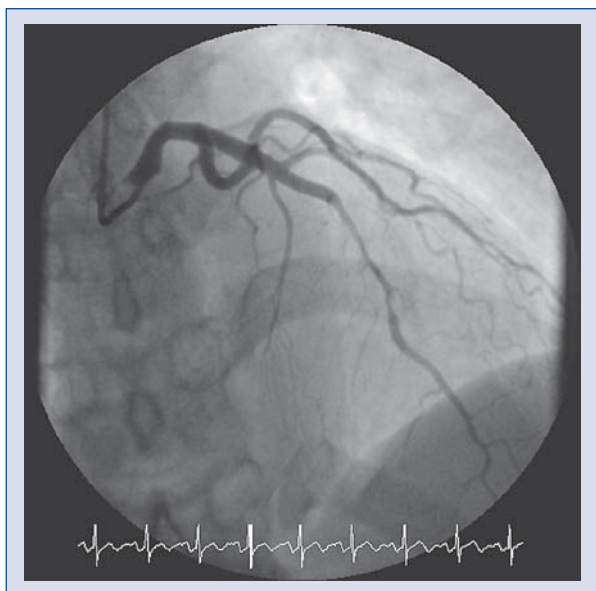


Figure 1. AP cranial view showing a long section of luminal narrowing in the mid left anterior descending artery

IVUS correctly identified the cause of luminal narrowing to be an extensive intramural hematoma (Fig. 2) with no evidence of dissection and minimal non-occlusive atheroma. In view of further chest pain and ischemia during angiography, a decision was made to treat the lesion by intracoronary stenting. This was achieved by implanting two overlapping Cypher stents (Cordis Corp, Bridgewater, NJ, USA). The final angiogram showed TIMI-3 flow with no residual luminal narrowing (Fig. 3). She was discharged on aspirin and clopidogrel and remains free of cardiac events at 12 months.

Discussion

A differential diagnosis of intramural hematoma should be considered in any middle-aged female with a paucity of risk factors for atherosclerosis, presenting with sudden onset of ischemic chest pain. Women appear to be primarily afflicted and the incidence is increased in the peripartum and postpartum periods, probably due to hormonal factors [2]. Other known risk factors are vasculitis, hypertension and illegal drugs [3]. The exact pathophysiology is unclear, but it is thought to be due to disruption of the vasa vasorum leading to hematoma formation in the media of the arterial wall [4, 5]. Intramural hematoma may occur as an isolated lesion, as in our case, or may be associated with coronary dissection which occurs secondarily to rupture

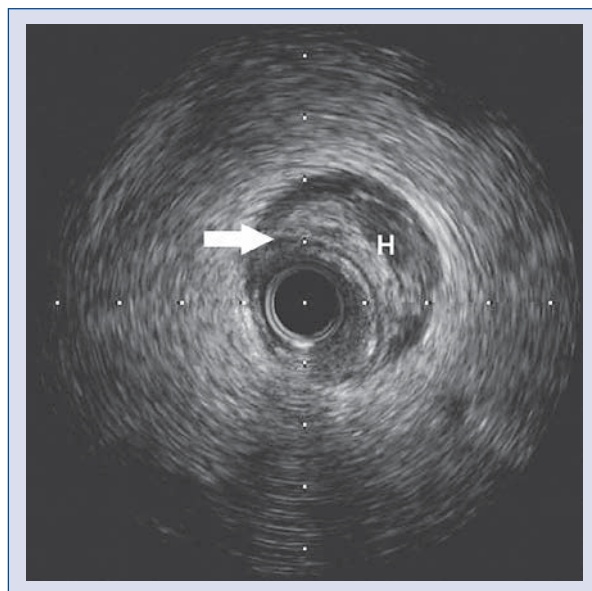


Figure 2. Intravascular ultrasound image showing an extensive intramural hematoma compressing the lumen of the left anterior descending artery. Hematoma (H) is clearly identifiable, external to the echo-lucent media (arrow). There is evidence of mild atheroma.

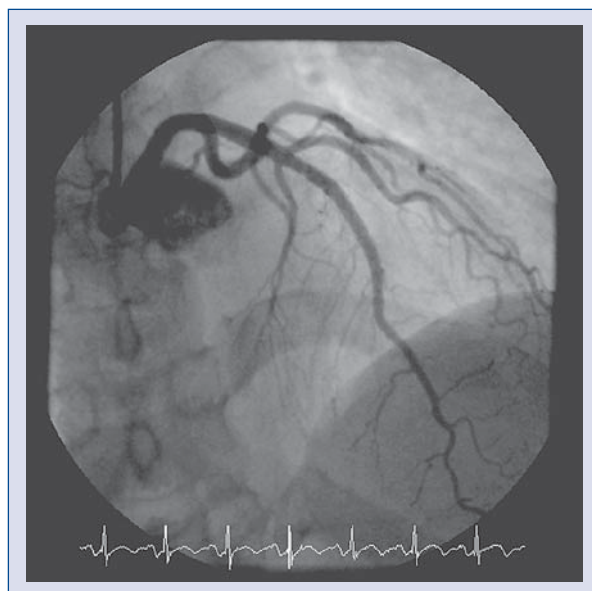


Figure 3. Final angiogram of the mid left anterior descending artery, showing TIMI 3 flow with no residual stenosis.

of the hematoma into the vessel lumen. In presentations where intramural hematoma is not associated with vessel dissection, the lesions may appear angiographically similar to a ruptured atheroscle-

rotic plaque. In this setting, IVUS is important in establishing the correct diagnosis and in planning management.

There is no consensus regarding the optimal management of intramural hematoma, and treatment is usually based on the presentation and presence of ongoing ischemia. Some cases have been managed with coronary bypass, others with intracoronary stenting [4]. However, complete and spontaneous resolution of occlusive intramural hematoma at 35 days confirmed by angiography and IVUS [6] has been reported in a stable patient. Therefore, taking into consideration conservative management in some cases, it is likely that isolated intramural hematoma causing luminal obstruction is frequently treated by coronary stenting without the clinician being aware of the true underlying diagnosis. Treatment by stenting may be prompted by ongoing ischemia, as in our case, or may occur more routinely when the lesion is misidentified as a ruptured atherosclerotic plaque. However, in cases treated by stenting, there have been reports of late stent malapposition, a risk factor for stent thrombosis, detected by IVUS at six months and thought to be due to resorption of the intramural hematoma over time [7].

This case highlights the importance of IVUS in correctly diagnosing isolated intramural hematoma. A high degree of suspicion should be held in young patients presenting with chest pain due to isolated coronary lesions and in whom there is a paucity of traditional risk factors for atheroscle-

rosis. When a diagnosis of intramural hematoma has been accurately identified, clinicians have the option of managing patients expectantly, in the absence of ongoing ischemia. Routine stenting for this condition may put the patient at unnecessary risk of stent thrombosis.

Acknowledgements

The authors do not report any conflict of interest regarding this work.

References

1. Basso C, Morgagni GL, Thiene G. Spontaneous coronary artery dissection: A neglected cause of acute myocardial ischaemia and sudden death. *Heart*, 1996; 75: 451-454.
2. Roth A, Elkayam U. Acute myocardial infarction associated with pregnancy. *J Am Coll Cardiol*, 2008; 52: 171-180.
3. Jaffe BD, Broderick TM, Leier CV. Cocaine-induced coronary-artery dissection. *N Engl J Med*, 1994; 330: 510-511.
4. Auer J, Punzengruber C, Berent R et al. Spontaneous coronary artery dissection involving the left main stem: Assessment by intravascular ultrasound. *Heart*, 2004; 90: e39.
5. Conraads VM, Vorlat A, Colpaert CG et al. Spontaneous dissection of three major coronary arteries subsequent to cystic medial necrosis. *Chest*, 1999; 116: 1473-1475.
6. Fujikura H, Hata Y, Morino Y et al. Images in cardiovascular medicine. Acute coronary syndrome due to intramural hematoma. *Circulation*, 2006; 114: e644-e645.
7. Sanchez-Recalde A, Moreno R, Jimenez-Valero S. Stenting of spontaneous intramural coronary haematoma: Long-term consequences. *Eur Heart J*, 2008; 29: 1593.