

Extraction of abandoned, potentially dangerous lead with uncovered proximal ending: A case report and method description

Andrzej Kutarski¹, Michał Chudzik², Andrzej Oszczygieł², Jerzy Krzysztof Wranicz²

¹Department of Cardiology, Medical University of Lublin, Poland

²Department of Electrophysiology, 1st Chair of Cardiology and Cardiosurgery, Medical University of Lodz, Poland

Abstract

In this study, we present the case of the extraction of a non-functioning, abandoned, chronically implanted nine year-old lead with proximal extended frayed ending, displaced spontaneously into the subclavian vein. The seemingly inaccessible lead was extracted from the body using the femoral approach. The lead was looped with a pig-tail catheter, standard guide-wire, and basket Dotter catheter, and the proximal ingrown ending was liberated. Finally, it was grasped with a basket catheter and its tip was liberated using oblique cut rotated internal sheath of a Femoral Working Station: using it as a Byrd dilator designed for subclavian approach. An additional difficulty was the risk of dislodging the correct endocardial lead in the pacemaker-dependent patient. The procedure indicates the necessity for the production of longer Byrd dilators designed for the femoral approach. (Cardiol J 2011; 18, x: xx–xx)

Key words: abandoned lead extraction, femoral approach for lead extraction

Introduction

Permanent pacing complications assume less-frequent lead fractures and more-frequent stays migration to short cutoff proximal part of the abandoned lead into the cardiovascular system [1, 2]. Such dropped-in proximal lead endings may remain fixed owing to the connecting tissue scar with vein wall. They usually affect local vein occlusion or they may migrate with the blood flow into the heart and pulmonary vascular bed. This may lead to very serious clinical consequences, such as venous stenosis (including superior and inferior cava vein syndrome), stenosis of tricuspid valve, and life-threatening arrhythmia, which are the most frequent and most dangerous consequences of a superfluous endocardial lead [3–7]. Sometimes, an endocardial

lead without isolation can damage the vein wall [8–11]. Hence, this lead may pose a potential threat to the patient if left in the venous system. In such circumstances, in patients with indications for CIED replacement or upgrading, extracting an abandoned endocardial lead should always be considered when contraindications are absent [12].

Case report

A 79 year-old male patient with arterial hypertension and coronary artery disease with stenocardia I Canadian Cardiovascular Society (CCS) had nine years previously been implanted with a VVI pacemaker (PM) with endocardial lead (Biotronik Synox 60 BP), introduced via the external left jugular vein because of permanent atrial fibrillation

Address for correspondence: Michał Chudzik, MD, Department of Electrophysiology, Medical University of Lodz, Sterlinga 1/3, 94–290 Łódź, Poland, tel/fax: +48 42 636 44 71, e-mail: michalchudzik@wp.pl

Received: 12.09.2010

Accepted: 29.09.2010

with complete atrioventricular block. Two years after PM implantation, an increase in pacing threshold over 4 V was noted. A new endocardial lead (Synox 60 BP) was implanted via the left subclavian vein. Simple traction for removal of the non-functioning lead was ineffective, and the old one was cut off and left in the subclavian region. For the next seven years, there was no problem with regard to pacing and sensing parameters. However, in March 2010, the patient was admitted to hospital for PM replacement. Unfortunately, the patient was still pacemaker-dependant. No abnormal finding was observed in the laboratory tests and ECHO parameters. Before carrying out the reimplantation procedure, fluoroscopy was performed, which revealed the presence of the abandoned lead. Therefore, we decided to perform lead extraction with PM reimplantation.

Procedure for pacemaker replacement and abandoned lead extraction

In the first instance PM was replaced in typical approach and lack of surgical attempt to extract the proximal part of the abandoned lead was confirmed (Fig. 1).

As the second step, the abandoned lead was extracted. Using the femoral vein approach, a pig-tail catheter was introduced into the right atrium. Unfortunately, neither the pig-tail catheter alone nor when combined with a standard guidewire, was able to liberate this ingrown part to vein wall proximal lead ending (Fig. 2A). Therefore, the next attempt was made with a loop of angiographic guidewire (Fig. 3C–E): The lead was looped by the guidewire introduced via the pig-tail catheter, and

the distal part of the guidewire was grabbed by a Dotter basket catheter (Cook) (Fig. 2B–F). The basket catheter was introduced by a Femoral Working Station (Cook). The essential element of the procedure was shifting the pig-tail catheter over the angiographic guidewire to make the loop sliding. This permitted equable drawing for both the extracted lead endings (Fig. 2E, F).

Manual traction applied to both the endings of the loop liberated the ingrown part of the lead (Fig. 3A, B) and progressed it into the inferior vena cava.

The free ending of the lead extracted was caught by Dotter basket (Fig. 4A, B). Subsequently, a Femoral Work Station 13 F sheath with oblique tip (manually cut) was slipped-on over the basket catheter and lead towards the right atrium (Fig. 4C, D). With the rotation of the catheter (in the same way as with Byrd dilators), we managed to liberate the distal part of the lead from the connecting tissue bridges and move it along (Fig. 4E–G).

The procedure was completed without any complications (Fig. 5). The duration of the entire procedure (from the first to the last fluoroscopy) was 76 min.

Post-operative progress

ECHO performed after the procedure did not reveal the presence of fluid in the pericardium, and only Igr tricuspid insufficiency was assessed. All other ECHO parameters and left ventricular function were accurate. There were no inflammation markers, and pacing and sensing parameters were appropriate. The patient is still on anticoagulant treatment, with heart failure in NYHA class II.

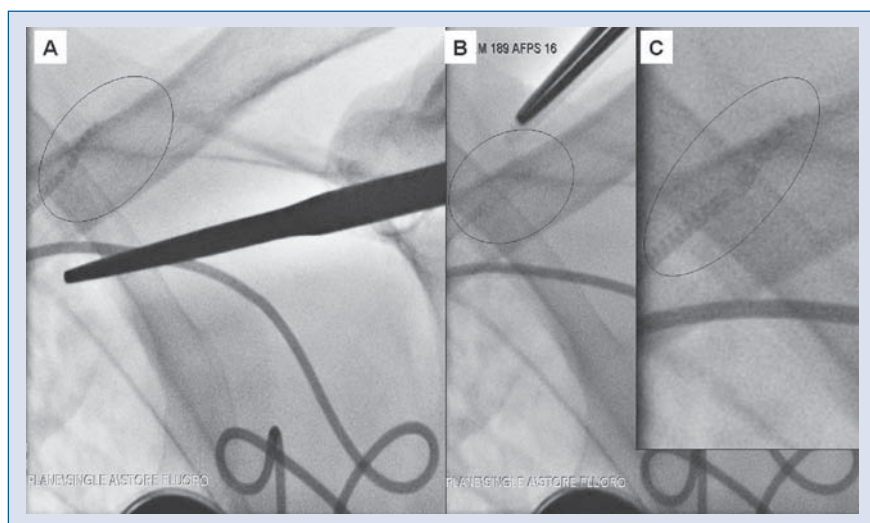


Figure 1A–C. Expanded and inaccessible proximal part of the abandoned lead in the subclavian vein.

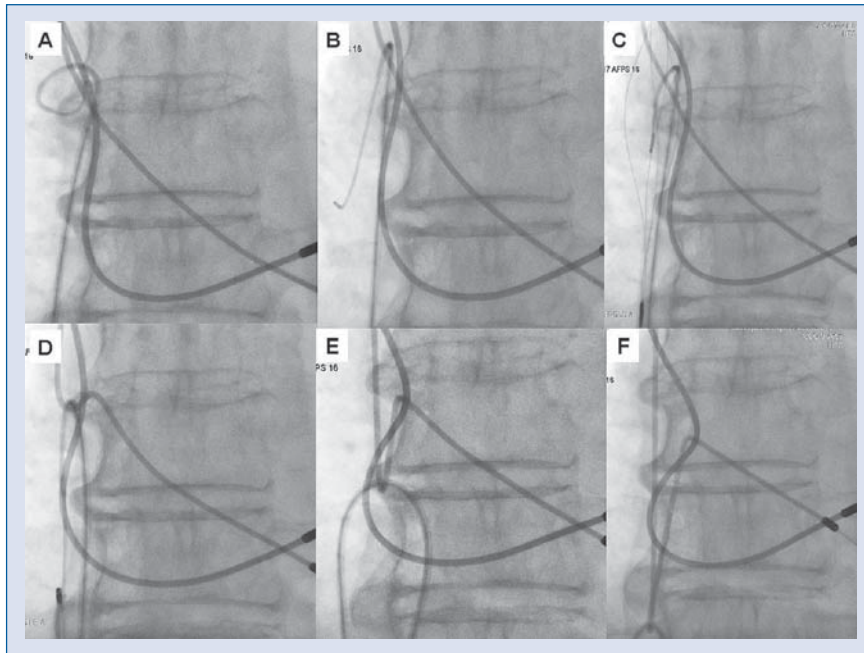


Figure 2. Looping of the extracted lead with pig-tail catheter containing guidewire inside (A–D). Pooling of the loop by hanging both the endings of the extracted lead (E, F).

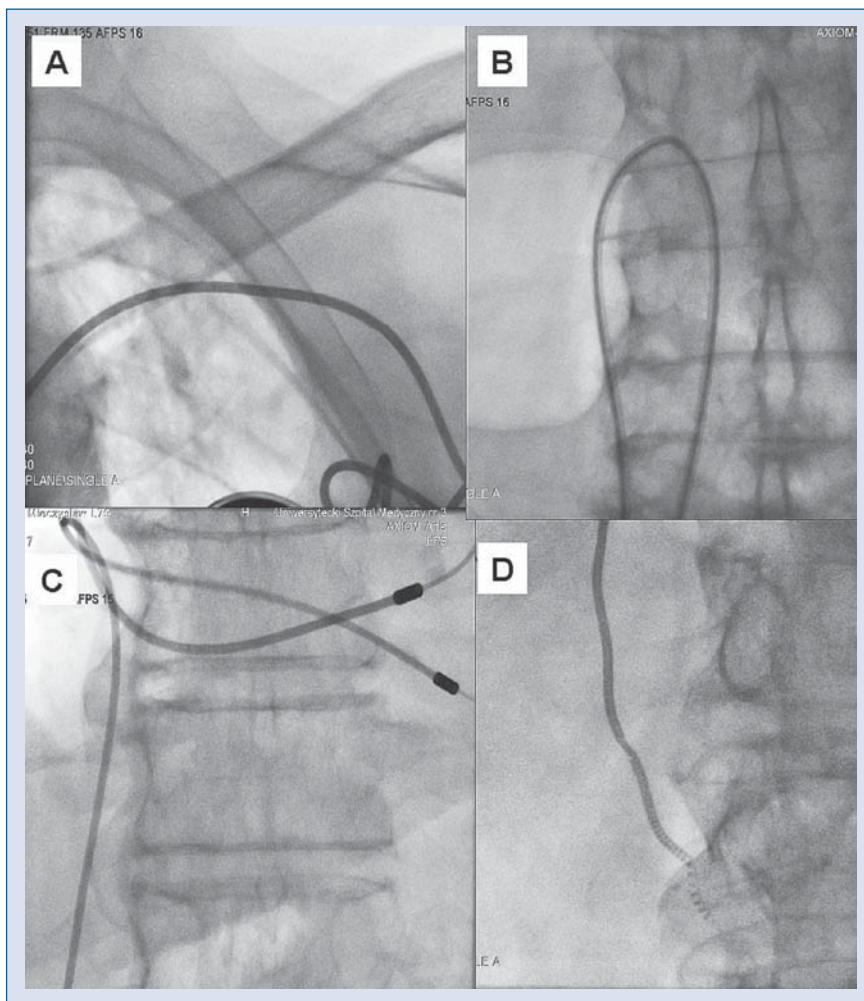


Figure 3. Extracted lead out of the subclavian vein (A), loop formed with pig-tail catheter with guidewire inside (B), previously inaccessible part of the endocardial lead in superior cava vein (C) visible, very dangerous, uncovered coil (D).

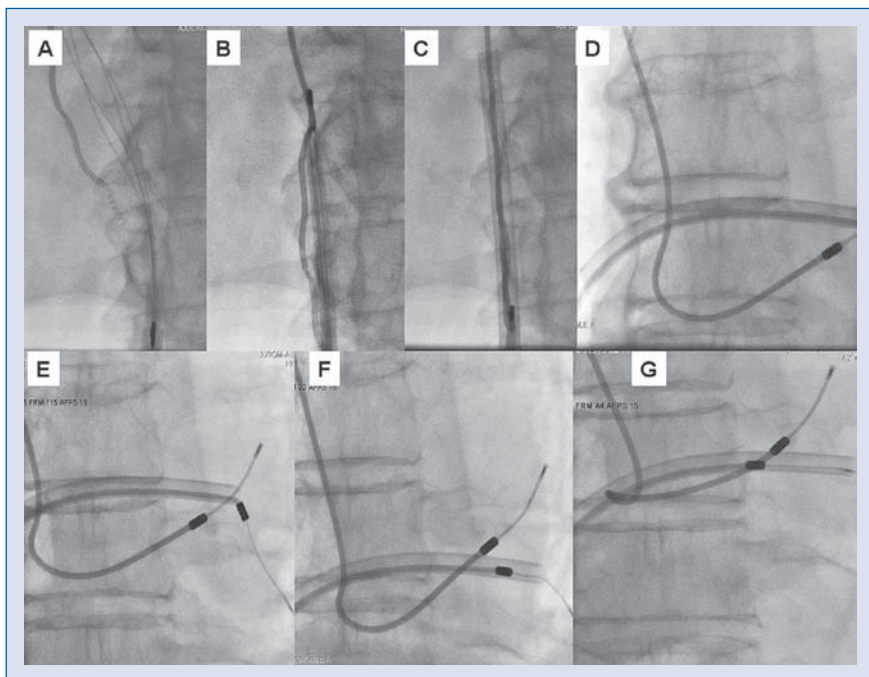


Figure 4 A–G. Liberation of the distal part of the extracted ventricular lead using two catheters that were the main parts of a Femoral Working Station (Cook) strained with Dotter basket. Temporary bending of the functional lead indicates the constancy of the connecting tissue scar surrounding the lead and its strong connection to the ventricular endocardium.

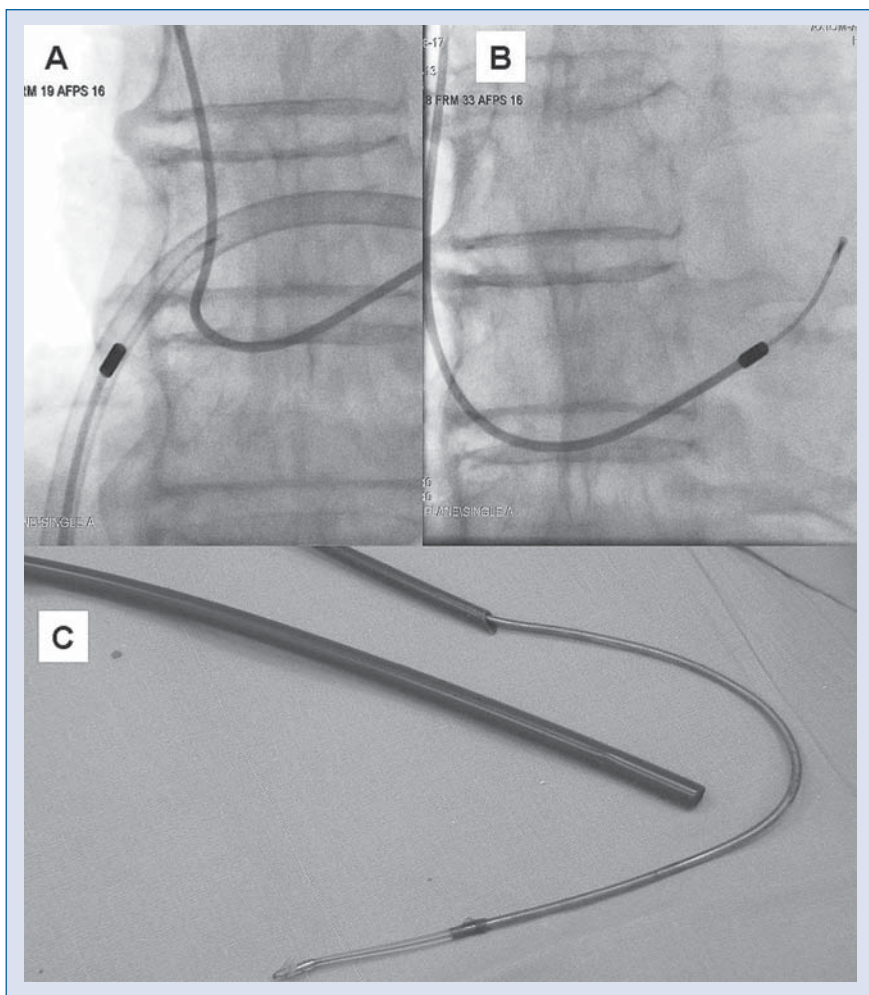


Figure 5. The final part of the procedure showing the extracted lead.

Discussion

Today, it is well known that endocardial leads are the weakest part of the whole pacing system [13]. Their loss of functionality may be due to mechanical damage or an unfavorable phenomenon where the tip and the endocardium connect (exit and entry block). Non-functioning superfluous abandoned leads may cause various complications in the future. Therefore, the current Heart Rhythm Society recommendation calls for lead extraction before such complications can develop [14].

Our case shows our technique for lead extraction, which has been successfully applied in patients with abandoned leads without accessible proximal part in the subclavian region. This procedure is much gentler when compared to other techniques (e.g. Needle's Eye[®]) in which special tools grasp leads very hard and do not allow for lead displacement and maintain correct balance when pulling out two lead's tail-ends. The use of a Femoral Work Station internal sheath, where the distal part is obliquely (manually) cut off, is similar to Teflon Byrd's dilators with a duration similar to that of the femoral approach. This technique permits effective lead liberation from the connecting tissue bridges, similarly to the subclavian approach.

Conclusions

This case report shows that the extraction of an abandoned lead without accessible proximal ending, using the femoral approach and drawing down with loop, including guidewire, pig-tail catheter, and basket catheter, is a possible and safe procedure, and may be performed without dislocating the functional lead. Furthermore, our unique technique for lead extraction, which is different from the femoral approach with oblique cutting-off catheter, and similar to Byrd's subclavian technique, has also been described. Additionally, we have shown that our technique requires a longer Byrd's catheter, which then can be used for the femoral approach.

Acknowledgements

The authors do not report any conflict of interest regarding this work.

References

1. Olgun H, Karagoz T, Celiker A, Ceviz N. Patient- and lead-related factors affecting lead fracture in children with transvenous permanent pacemaker. *Europace*, 2008; 10: 844–847.
2. Thomson JD, Blackburn ME, Van Doorn C, Nicholls A, Watterson KG. Pacing activity, patient and lead survival over 20 years of permanent epicardial pacing in children. *Ann Thorac Surg*, 2004; 77: 1366–1370.
3. Lonyai A, Dubin AM, Feinstein JA, Taylor CA, Shadden SC. New insights into pacemaker lead-induced venous occlusion: Simulation-based investigation of alterations in venous biomechanics. *Cardiovasc Eng*, 2010; 10: 84–90.
4. Korkeila P, Nyman K, Ylitalo A et al. Venous obstruction after pacemaker implantation. *Pacing Clin Electrophysiol*, 2007; 30: 199–206.
5. Stauthammer C, Tobias A, France M, Olson J. Caudal vena cava obstruction caused by redundant pacemaker lead in a dog. *J Vet Cardiol*, 2009; 11: 141–145.
6. Aryana A, Sobota KD, Esterbrooks DJ, Gelbman AI. Superior vena cava syndrome induced by endocardial defibrillator and pacemaker leads. *Am J Cardiol*, 2007; 99: 1765–1767.
7. Shimada Y, Yaku H, Kawata M et al. An operative case of inferior vena cava stenosis due to fibrosis around permanent pacemaker leads. *Pacing Clin Electrophysiol*, 2002; 25: 223–235.
8. Ruparelia N, Newton J, Ormerod OJ, Bhindi R. Percutaneous retrieval of an embolized pacemaker lead from the pulmonary artery. *Int J Cardiol*, 2009 [Epub ahead of print].
9. Lorscheid A, De Boeck BW, Guyomi SH, Klöpping C. A wandering defibrillator lead. *Eur J Echocardiogr*, 2009; 10: 156–159.
10. Golzio PG, Bongiorni MG, Chiribiri A, Franco E. Extraction of the inner coil of a pacemaker lead slid into the pulmonary artery. *Pacing Clin Electrophysiol*, 2007; 30: 273–275.
11. Tatou E, Lefez C, Reybet-Degat O et al. Intrapulmonary artery and intrabronchial migration and extraction of a fragment of J-shaped atrial pacing catheter. *Pacing Clin Electrophysiol*, 1999; 22: 1829–1830.
12. Wilkoff BL, Love CJ, Byrd CL et al.; Heart Rhythm Society; American Heart Association. Transvenous lead extraction: Heart Rhythm Society expert consensus on facilities, training, indications, and patient management: This document was endorsed by the American Heart Association (AHA). *Heart Rhythm*, 2009; 6: 1085–1104.
13. Arnsbo P, Møller M. Updated appraisal of pacing lead performance from the Danish Pacemaker Register: The reliability of bipolar pacing leads has improved. *Pacing Clin Electrophysiol*, 2000; 23: 1401–1406.
14. Klug D, Jarwé M, Messaoudé SA et al. Pacemaker lead extraction with the needle's eye snare for countertraction via a femoral approach. *Pacing Clin Electrophysiol*, 2002; 25: 1023–1028.