

Late diagnosis of congenital cardiovascular defect

Radosław Zwoliński, Iwona Cygankiewicz, Arkadiusz Ammer, Ryszard Jaszewski

Department of Cardiosurgery, 1st Chair of Cardiology and Cardiosurgery,
Medical University of Lodz, Poland

Abstract

Coarctation of the aorta (CoA) is a common congenital anomaly that is usually treated in infancy or childhood. Adult patients with coarctation have a high incidence of associated cardiac disorders, including valve diseases, atrial fibrillation and ischemic heart disease. Most patients with uncorrected CoA die before reaching the age of 50 from complications such as myocardial infarction, intracranial hemorrhage, congestive heart failure (HF), infective endocarditis or aortic dissection.

We report the case of a 65 year-old woman admitted to hospital with symptoms of heart failure NYHA class IV. She had been treated for several years for refractory arterial hypertension and concomitant stenocardia (II CCS). The symptoms of HF had been increasing over several months. Outpatient echocardiography examination revealed significant, increasing mitral and tricuspid valve regurgitation with progressive left ventricular dysfunction. The patient was referred for surgical repair of the mitral and tricuspid valves. In-hospital echocardiography and angiography revealed descending aorta discontinuity at the level of the aortic isthmus. This congenital disease revealed during hospitalization was determined to be the underlying cause of all the symptoms the patient presented. Due to the clinical status of the patient, she was discharged from surgical procedures and put on medication. (Cardiol J 2011; 18, x: xx–xx)

Key words: congenital heart defect, coarctation of the aorta, heart failure

Coarctation of the aorta (CoA) is the eighth commonest congenital heart defect. It is twice as common in males as in females. In infancy it can lead to severe heart failure (HF) which may be fatal and requires urgent surgical treatment [1]. Mortality from severe aortic coarctation and the frequency of late diagnoses have decreased significantly over the past 30 years. Due to the wider use echocardiography, diagnoses are made early in most children so they can be treated before the age of four using surgical or interventional techniques. Diagnosis of CoA in patients over 65 years is very rare. According to Campbell [1], untreated CoA leads to the death of 90% of patients before the age of 50.

A 65 year-old woman had been treated for several years for resistant hypertension and had a four

year history of congestive HF aggravated in the last four months to III/IV NYHA class, with concomitant atrial fibrillation. Stenocardial symptoms had been escalating over the past three months, reaching II CCS.

Out-patient echocardiography was performed four times between 1999 and 2004. It revealed moderate mitral and severe tricuspid insufficiency, with decreased left ventricle global contractile function (ejection fraction 30%).

The patient was admitted for evaluation and qualification for surgical reconstruction of the mitral and tricuspid valves. On admission, she presented with cyanosis, peripheral edema, hepatomegaly, jugular veins overfilling and pulsation and rest dyspnea.

Address for correspondence: Radosław Zwoliński, Medical University of Lodz, ul. Sterlinga 1/3, 91–425 Łódź, Poland, tel/fax: +48 42 6644340, e-mail: radekzwolinski@poczta.onet.pl

Received: 20.10.2010

Accepted: 26.12.2010

Dry rales and fine rales were audible. The pulse was irregular, about 100 bpm, symmetric on upper and lower limbs. The ECG revealed atrial fibrillation. On cardiac auscultation, S2 splitting over pulmonary valve area with grade 3/6 holosystolic murmur were audible. Chest X-ray revealed cardiomegaly, enlarged pulmonary hila and increased pulmonary vasculature, especially over the left inferior pulmonary area.

Two-dimensional echocardiography showed global hypokinesis with left ventricular ejection fraction (LVEF) of 30%, moderate left atrium enlargement, moderate mitral valve insufficiency with concomitant leaflet and subvalvular apparatus fibrosis, severe tricuspid valve insufficiency with concomitant pulmonary hypertension (75 mm Hg) and mild aortic regurgitation. Suprasternal notch projection revealed the lack of descending aorta inferior to the subclavian artery (Fig. 1). Continuous wave Doppler examination showed laminar blood flow (1.1 m/s), with no flow in the isthmus.

Due to coexisting stenocardia and the suspicion of CoA, the patient underwent selective coronaryography and aortography which revealed a slightly widened aortic arch in its proximal segment with total discontinuity distal to the left subclavian artery. The length of gap was 1 cm. The collateral circulation was very well developed, mainly through the left subclavian artery (Fig. 2A, B).

Cardiac catheterization revealed no significant lesion in coronary vessels over 75%.

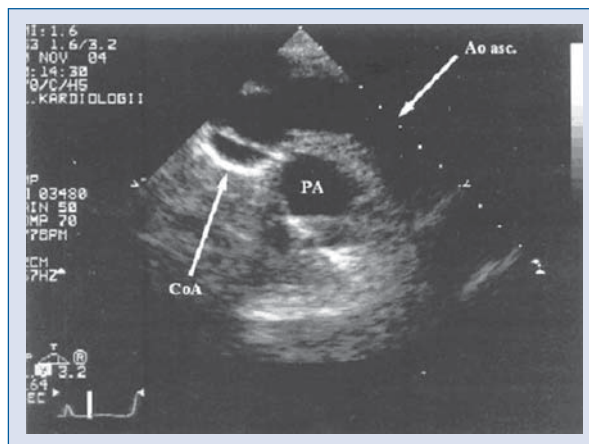


Figure 1. Aortic arch in echocardiography (jugular incisure projection); CoA — coarctation of aorta; Ao asc. — ascending aorta; PA — pulmonary artery.

Neither heart catheterization nor echocardiographic examination revealed the presence of patent arterial duct.

Based on the clinical picture, the patient was disqualified from surgical treatment. It was also impossible to perform percutaneous transluminal aortic balloon angioplasty. The patient was qualified for medical treatment.

During four months of follow-up, LVEF decreased to 10% and treatment focused on alleviating symptom in the terminal stage of the disease.

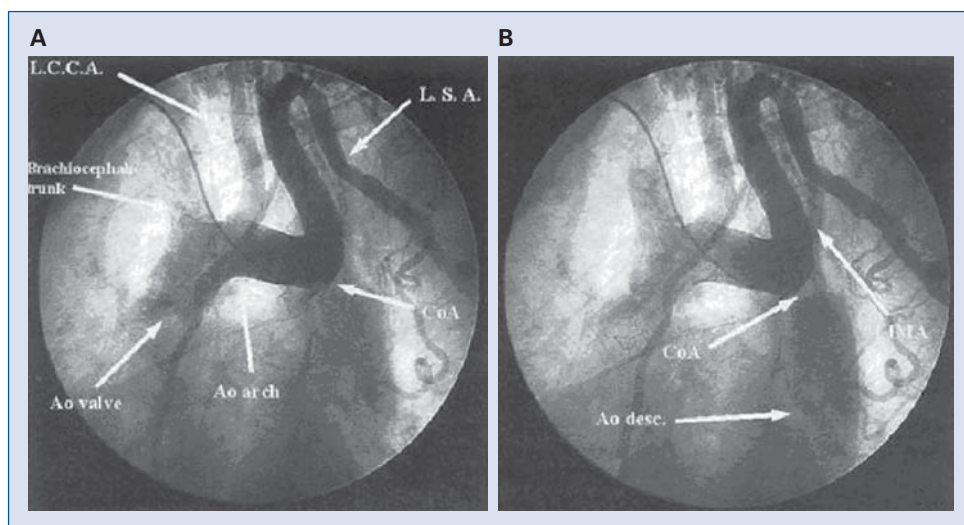


Figure 2. Aortic arch catheterization through right radial artery access; **A.** There is no contrast flow to the descending aorta; **B.** Descending aorta becomes visible by collateral circulation; Ao valve — aortic valve; Ao arch — aortic arch; CoA — coarctation of aorta; L.S.A. — left subclavian artery; L.C.C.A. — left common carotid artery; LIMA — left internal mammary artery; Ao desc. — descending aorta.

Coarctation of the aorta is defined as a congenital narrowing of the lumen of the aorta, adjacent to the site of attachment of ductus arteriosus. It may be tubular, several millimeters in length or localized shelf or projection. Tubular lesion may begin from left subclavian artery and end near insertion of ligamentum arteriosum, or may be longer. In the membranous form of CoA, slit-like lumen of aorta may in time close with concomitant development of collateral circulation. This mechanism appears the likeliest cause of coarctation in the case described above.

A diagnosis of aortic coarctation in an adult is uncommon, but an accidental diagnosis of this lesion in a 65 year-old person is a true rarity. We have found a few reports concerning patients older than 50 operated on for CoA [2]. In two cases the patients were 65 [3, 4]. The problem of late diagnosis of CoA in adults with a long history of hypertension is also emphasized [5]. Our patient had delivered two healthy children through natural births at home in 1965 and 1968. It is impossible to determine the progression of the defect by that time, whether it was still narrow coarctation or interrupted aortic arch with developed extensive collateral circulation. Cases of CoA in pregnant women previously treated for hypertension or with new onset hypertension have been reported in the literature [6]. Singh et al. [7] described a young woman with CoA who gave birth naturally. Most authors suggest the necessity of abdominal delivery [8, 9]. Our case illustrates the problems resulting from too late a diagnosis. The patient had been treated for hypertension for several years, but the correct diagnosis was made when the possible treatment options were no longer applicable.

Clinically, the diagnosis of CoA in our case was extremely difficult. In physical examination normal constitution without upper half of the body hypertrophy, symmetric femoral pulse, without typical radial-femoral pulse delay due to complete arrhythmia, lack of typical X-ray findings. From 1999 through 2004 the patient underwent echocardiographic examination four times by independent echocardiographers, none of whom diagnosed CoA. We may assume that suprasternal projection was not routinely applied.

The patient has been treated for systemic hypertension for several years. After a diagnosis of

mitral and tricuspid valve regurgitation, the treatment was modified, yet nevertheless successive degeneration of valves was observed. Cardiosurgical consultation was performed after the appearance of congestive cardiomyopathy and stenocardia. Unfortunately, due to severe heart insufficiency and high operative risk, the patient was disqualified from surgical treatment. It was also impossible to perform percutaneous aortoplasty and medical treatment did not improve the symptoms.

Late diagnosis of a very rare case of isthmic CoA with interrupted aortic arch in a 65 year-old woman was reported. Clinically, a case of long-term hypertension with increasing mitral and tricuspid valves insufficiency, atrial fibrillation, progression of left ventricle dysfunction and finally stenocardia is a diagnostic challenge. On the other hand, early diagnosis of CoA established on proper echocardiographic examination would have given a chance of total surgical repair.

Acknowledgements

The authors do not report any conflict of interest regarding this work.

References

1. Campbell M. Natural history of coarctation of the aorta. *Br Heart J*, 1970; 32: 633–640.
2. Almeida de Oliveira S, Lisboa LA, Dallan LA, Abreu FCA, Rochitte CE, de Souza JM. Extraanatomic aortic bypass for repair of aortic arch coarctation via sternotomy: Midterm clinical and magnetic resonance imaging results. *Ann Thorac Surg*, 2003; 76: 1962–1966.
3. Petrik PV, Livesay JJ, Flamm SD. Presentation of infantile aortic coarctation in an adult. *Tex Heart Inst J*, 2001; 28: 304–307.
4. Aris A, Subirana MT, Ferres P, Torner-Soler M. Repair of aortic coarctation in patients more than 50 years of age. *Ann Thorac Surg*, 1999; 67: 1376–1379.
5. Varma C, McLaughlin PR, Hermiller JB, Tavel ME. Coarctation of the aorta in adult. Problems of diagnosis and management. *Chest*, 2003; 123: 1749–1752.
6. Sherer DM. Coarctation of the descending thoracic aorta diagnosed during pregnancy. *Obstet Gynecol*, 2002; 100: 1094–1096.
7. Singh BM, Kriplani A, Bhatla N. Vaginal delivery in a woman with uncorrected coarctation of aorta. *J Obstet Gynaecol Res*, 2004; 30: 24–26.
8. Walker E, Malins AF. Anaesthetic management of aortic coarctation in pregnancy. *Int J Obstet Anesth*, 2004; 13: 266–270.
9. Beauchesne LM, Connolly HM, Ammash NM, Warnes CA. Coarctation of the aorta: Outcome of pregnancy. *J Am Coll Cardiol*, 2001; 15: 1728–1733.