

Left ventricular ballooning syndrome due to vasospasm of the middle portion of the left anterior descending coronary artery

Miguel Fiol¹, Andrés Carrillo¹, Alberto Rodriguez¹,
Jaime Herrero¹, Javier García-Niebla²

¹Hospital Son Espases, Palma de Mallorca, Spain

²Servicios Sanitarios del Area de Salud de El Hierro, Valle del Golfo Health Center, Canary Islands, Spain

Abstract

We report a case that shows vasospasm to be one of the mechanisms responsible for left ventricular ballooning syndrome. Our case suggests that identical ventriculographic findings in patients with tako-tsubo syndrome and those with coronary vasospasm of a long left anterior descending artery coronary artery may be due to a common etiology. (Cardiol J 2011; 18, X: xx–xx)

Key words: left ventricular ballooning syndrome, vasospasm

Introduction

Since the first description of left ventricular ballooning syndrome (LVBS), otherwise known as tako-tsubo syndrome, coronary vasospasm has been put forward as one of the pathophysiological mechanisms involved [1–5]. This is a rare syndrome [6] and little information is available on its treatment and long-term prognosis.

Case report

We report the case of a 53 year-old woman, with hypercholesterolemia of 220 mg/dL as the only known cardiovascular risk factor, who originally consulted in 2003 due to nocturnal, prolonged angina-like chest pain, unrelated to any form of stress. Electrocardiogram (ECG) at admission showed a pattern of subepicardial lesion in precordial leads V1 to V6 and inferior leads II, III, and aVF (Fig. 1A). Emergency coronary angiography showed lesion-free coronary arteries, a long left anterior descending (LAD) artery that wrapped around the cardiac

apex, with reduced diameter from the mid-distal portion (Fig. 1B), and a typical image of tako-tsubo syndrome (Fig. 1C), left ventricular end-diastolic pressure of 21 mm Hg and an ejection fraction of 50%. Transthoracic echocardiogram showed akinesia of the septal-mid-apical, antero-apical and infero-apical segments. Peak CPK was 760 IU/L, CK-MB 74 IU/L and troponin I 20 ng/mL.

After initiating treatment with intravenous nitroglycerin (subsequently suspended due to headache), and diltiazem 300 mg/day, Q waves appeared in leads II, III, aVF, and V2–V6 with positive T wave persistence but also ST segment depression > 70%. However, over the following few days, vector recovery was observed in all the affected leads, along with improved echocardiographic parameters.

Until 2010, the patient was asymptomatic, receiving single daily doses of diltiazem 300 mg, aspirin 100 mg, enalapril 10 mg and simvastatin 40 mg. She then consulted for a new episode of anginal pain, similar to that previously experienced but less intense, and again unrelated to stress. The ECG showed no significant alterations (Fig. 2A), necrosis

Address for correspondence: Miguel Fiol, MD, PhD, Hospital Son Espases, Carretera de Valldemosa 79, 07010 Palma de Mallorca, Spain, tel: +34646956100, e-mail: miguel.fiol@ssib.es

Received: 25.10.2010

Accepted: 07.01.2010

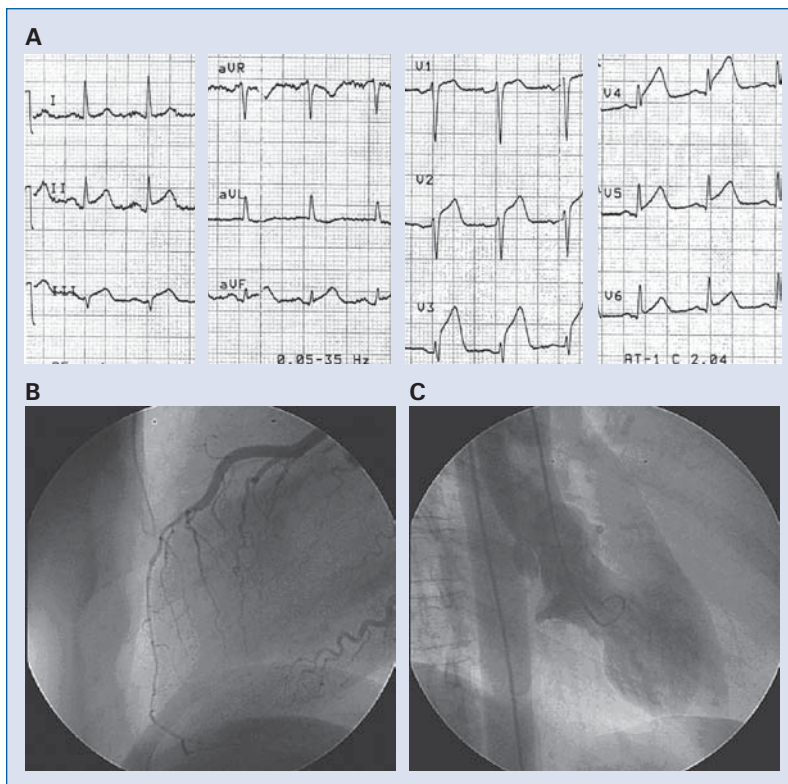


Figure 1. A. Electrocardiography at admission shows a pattern of subepicardial lesion in all precordial and inferior leads; B. Cardiac ventriculography shows a spasm of the middle portion of a long left anterior descending artery wrapped around the cardiac apex; C. Cardiac ventriculography shows a typical image of left ventricular ballooning.

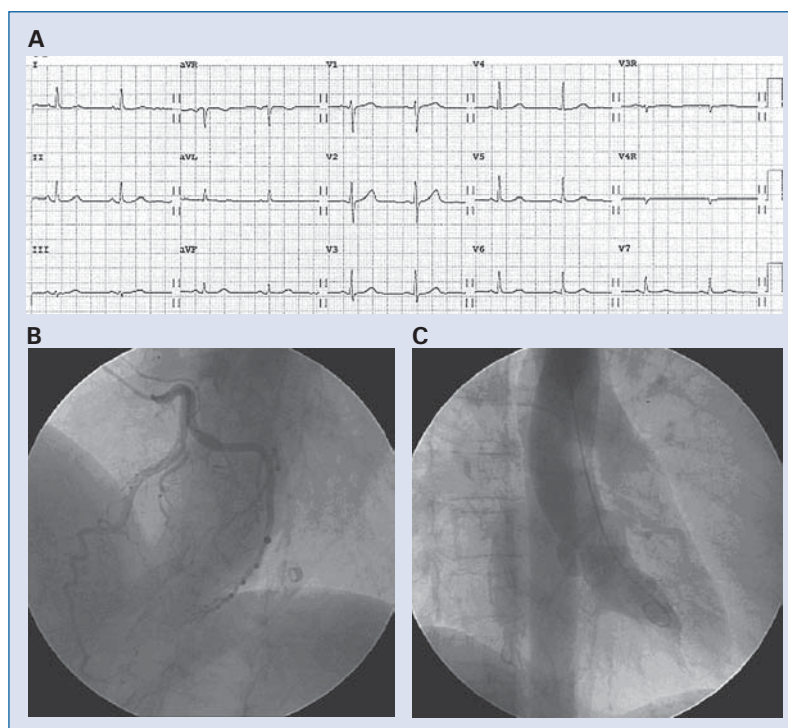


Figure 2. A. Electrocardiographic tracing with normal characteristics; B. Cardiac ventriculography shows no evidence of the coronary artery spasm observed on the previous admission; C. Cardiac ventriculography shows no evidence of the left ventricular ballooning observed on the previous admission.

markers were negative, there was no evidence of coronary vasospasm (Fig. 2B), and no signs of tako-tsubo syndrome in the ventriculogram (Fig. 2C).

Discussion

Ibanez et al. [7] suggested a common etiology in ischemic tako-tsubo syndrome and acute myocardial infarction secondary to LAD artery occlusion, both with a long wrap-around LAD artery, since cardiac ventriculography findings are identical. Furthermore, in five cases of tako-tsubo syndrome [8] with insignificant angiographic atherosclerosis, the same authors reported that intravascular ultrasound detected a non-occlusive plaque in the middle portion of the LAD artery, which suggests that in some cases the appearance of LVBS is actually an acute coronary syndrome with early reperfusion (aborted infarct) in patients with a long wrap-around LAD artery.

According to some authors [9], vasospasm in a single artery as the pathophysiological mechanism of LVBS is improbable because the affected territory is too limited. However, in our case, a spasm located in the middle portion of a long LAD artery that wrapped around the cardiac apex gave rise to the LVBS.

This case illustrates that vasospasm is one of the mechanisms responsible for LVBS, and that treatment with calcium antagonists is effective in maintaining the patient asymptomatic for long periods of time, but also that there may be subsequent episodes of less intense chest pain without hemodynamic compromise.

Several aspects of this case are noteworthy. First, angina-like chest pain was not preceded by an episode of emotional or physical stress, which may play a key role in the pathogenesis of the disorder. Secondly, the recurrence of chest pain occurs in no more than 10% of cases, according to previous studies [10]. Thirdly, the prognosis was good [10].

Our case suggests that the identical ventriculographic findings in patients with tako-tsubo syn-

drome and those with coronary vasospasm of a long LAD coronary artery may be due to a common etiology.

Acknowledgements

The authors do not report any conflict of interest regarding this work.

References

1. Angelini P. Transient left ventricular apical ballooning: A unifying pathophysiologic theory at the edge of Prinzmetal angina. *Catheter Cardiovasc Interv*, 2008; 71: 342–352.
2. Haghi D, Suselbeck T, Wolpert C. Severe multivessel coronary vasospasm and left ventricular ballooning syndrome. *Circulation*, 2009; 2: 268–269.
3. Sansen S, Holvoet G. Takotsubo cardiomyopathy presenting as multivessel coronary spasm syndrome: Case report and review of the literature. *Acta Cardiol*, 2007; 62: 507–511.
4. Cheng TO. Whether you call it apical ballooning syndrome or takotsubo cardiomyopathy, it is due to coronary artery spasm with or without underlying atherosclerosis. *Catheter Cardiovasc Interv*, 2009; 73: 717.
5. Nojima Y, Kotani J. Global coronary artery spasm caused tako-tsubo cardiomyopathy. *J Am Coll Cardiol*, 2010; 55: 9.
6. Tsuchilashi K, Ueshima K, Uchida T et al. Transient left ventricular apical ballooning without artery stenosis: A novel heart syndrome mimicking acute myocardial infarction. *J Am Coll Cardiol*, 2001; 38: 11–18.
7. Ibañez B, Navarro F, Farré J et al. Tako-Tsubo transient left ventricular apical ballooning is associated with a left anterior descending coronary artery with a long course along the apical diaphragmatic surface of the left ventricle. *Rev Esp Cardiol*, 2004; 57: 209–216.
8. Ibañez B, Navarro F, Córdoba M, Marcos-Alberca P, Farré J. Tako-tsubo transient left ventricular apical ballooning: Is intravascular ultrasound the key to resolve the enigma? *Heart*, 2005; 91: 102–104.
9. Stöllberger C, Finsterer J, Schneider B. Transient left ventricular dysfunction (tako-tsubo phenomenon): Findings and potential pathophysiological mechanisms. *Can J Cardiol*, 2006; 22: 1063–1068.
10. Elesber AA, Prasad A, Lennon RJ et al. Four-year recurrence rate and prognosis of apical ballooning syndrome. *J Am Coll Cardiol*, 2010; 50: 448–452.